

WHAT IS ROOT CANAL TREATMENT?

I have a number of papers at toothvet.ca discussing endodontic anatomy, physiology, pathology and diagnosis. What I have not yet written about is what we do about these diseased teeth.

Be sure to review these papers as background information:

[Endodontic Anatomy and Physiology](#)

[Endodontic Diagnosis](#)

[The Chevron Sign](#)

[Uncomplicated Crown Fractures](#)

[Vital Pulpotomy vs Total Pulpectomy](#)

[Crown Reduction](#)

Now let us assume that you have diagnosed a mature tooth with endodontic (pulp) disease. What can be done about it?

One option is extraction.

The only other option is 'root canal treatment'.


"Wait and See" or monitoring are NOT options and neither is antibiotic treatment.

Please take note: What follows is NOT intended to teach anyone how to do root canal treatment. All endodontic treatments should definitely be considered [Not For the Casual Operator](#). In fact, it is a subject of some debate among veterinary dental specialists whether it is really appropriate for us to offer introductory wet-labs in endodontics to general practitioners.

The concern is that a well-meaning general practitioner takes an introductory 3-hour wet-lab or two and thinks that has prepared them to offer these service to live patients. The results can be disastrous (and there are many examples). Many human dentists (DDSs) do not perform root canal therapy themselves, preferring to refer these cases to board-certified endodontic specialists.

If you are really interested in offering endodontic therapies for your patients, step one would be to obtain and read (cover to cover) the latest edition of Pathways of the Pulp. It is the introductory textbook on the subject for students studying human dentistry. There are some anatomic

differences between human and dog/cat teeth, but the principles of treatment apply equally well to our patients with a few minor modifications.

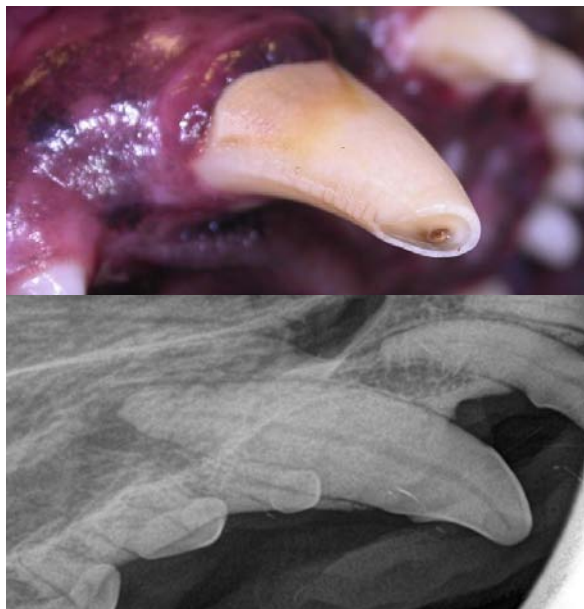

If reading such a weighty tome seems like too much bother, then do not even consider trying to learn endodontics.

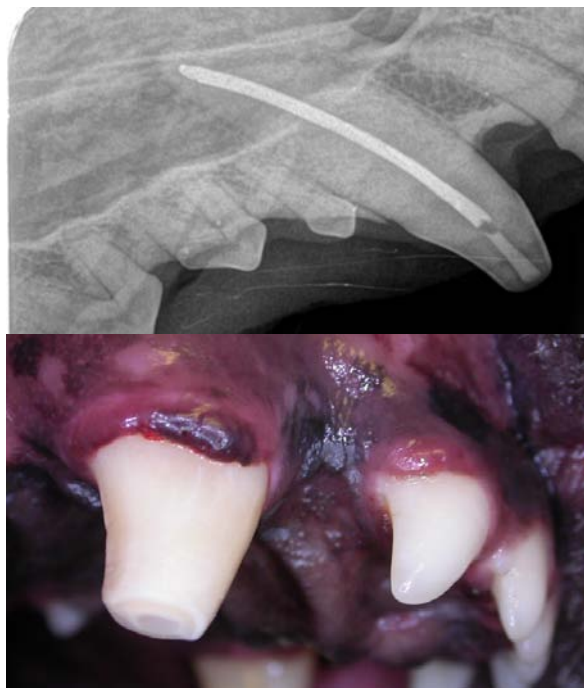If you are going to do something, do it right. If you are not going to do it right, do not do it at all.

Having read Pathways of the Pulp as well as attending lectures on veterinary endodontics, your next step would be to attend several wet labs, obtain a large array of materials and instrumentation, practice on many extracted teeth or cadaver specimens and have that work evaluated by a veterinary dental specialist before ever offering the treatment for a live patient.

If you are not willing to make this commitment, then just extract or refer. This is not something in which you can dabble. Go big or don't go.



This fractured right maxillary canine tooth has suffered pulp exposure and septic pulp necrosis. The fracture is limited to the crown of the tooth and the pulp chamber is relatively small. This tooth was an excellent candidate for root canal treatment and that is what was done.



The purpose of this paper is to outline to the reader what is involved in root canal treatment so that they (veterinarians and pet owners) can make informed decisions regarding which treatment option (extraction or root canal treatment) to select.

Pros & Cons

As stated, for mature teeth with endodontic disease, the treatment options are extraction or root canal treatment. The link about [vital pulpotomy versus total pulpectomy](#) discusses the treatment options for immature teeth.

The two options each have their own theoretical advantages and disadvantages which may be modified by the amount and type of damage to the tooth.

For extraction:

Pros	Cons
Less technically difficult	Loss of form and function of the tooth
Requires far less equipment	Creates a wound that must heal and is at risk of failing to heal
Is a "final" solution	More surgical trauma and so more post-operative pain
In many (but not all) situations, is less expensive	Can be awfully simple or simply awful!
Once the wound has healed, no need for follow-up.	

For Root Canal therapy:

Pros	Cons
No wound to heal (or fail) so immediate return to normal activity	Requires a lot of extra training.
Preserves the form and function of the tooth	Requires lots of special equipment & materials
Far less post-operative pain	In most cases, takes longer than extraction and so usually more expensive
Should have periodic radiographic follow-up	

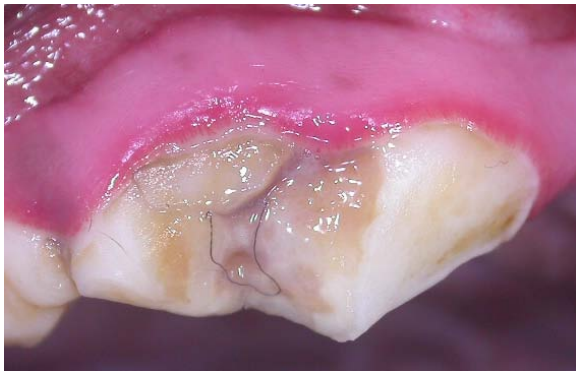With those general thoughts in mind, you need to consider some modifying factors.

How important is the tooth?

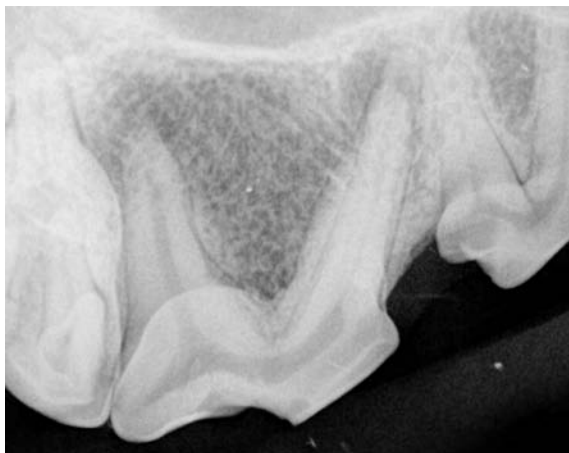Root canal treatment to preserve a canine tooth or a mandibular first molar makes a lot of sense as these are large, functionally important teeth and extracting them can be challenging and creates a large wound to manage. Doing root canal treatment on a 1st premolar tooth makes no sense to me as these small teeth are relatively unimportant and usually very easy to extract, leaving only a small wound.

Does the tooth have any other compromising factors?

A tooth may have endodontic disease and periodontal disease at the same time. Or the fracture may extend well below the gum line. Or there may be root resorption ongoing. Before making the final treatment decision, it is important to evaluate the tooth thoroughly (under anesthetic and including dental radiographs) to determine if the tooth truly is a candidate for root canal therapy.

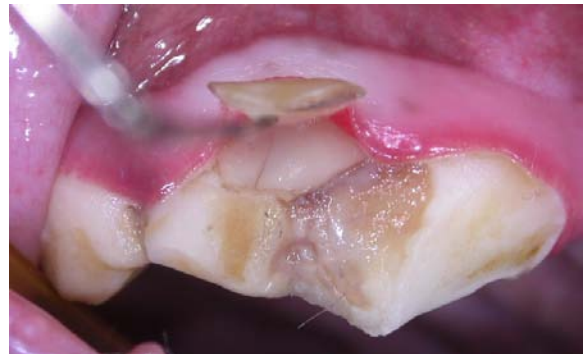

This right upper 4th premolar tooth has a slab fracture without obvious pulp exposure. Despite the lack of obvious pulp exposure, the radiograph showed us this:



There were small but obvious apical lucencies at all three root tips indicating that there was septic pulp necrosis and chronic apical periodontal infection.

There was also a slab fragment attached to the gingiva indicating that the damage extended below the gum line, creating periodontal concerns that might mean this tooth is a "Humpty-Dumpty" and so in need of extraction depending on how far below the gum line the damage extends. If the damage goes only a couple of millimeters below the gum line AND the dog has good periodontal health overall AND the owner really wishes to save the tooth AND the owner will brush the tooth daily AND the owner will bring the patient in a year for re-evaluation of the situation AND the owner is willing to accept that the tooth may fail, then the tooth may be a candidate for root canal therapy. Otherwise it requires extraction.

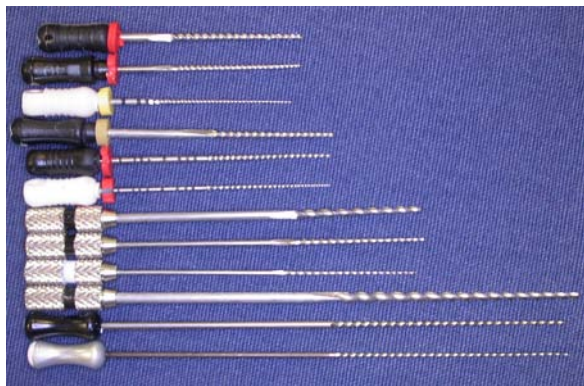


Upon lifting the flap, I found a vertical crack in the tooth that extended well up the root into the socket. This was the likely portal of entry for bacteria leading to septic pulp necrosis and it meant that the tooth was FUBAR. I extracted.


Equipment and materials

As well as high and low-speed dental hand pieces and intra-oral dental radiography that all dental suites should have, there are a lot of specific instruments and materials required to perform root canal therapy. This would include:

- a variety of lengths, styles and sizes of endodontic files (hand and power driven)
- a variety of lengths, styles and sizes of pluggers and spreaders (cold and heated)
- a variety of lengths and sizes of irrigation needles
- a variety of irrigation and disinfecting solutions



A selection of K-files in lengths (top to bottom) 25 mms, 31 mms, 40 mms, 60 mms. The ones shown are sizes 80, 40 and 15. A typical set of files has sizes 15, 20, 25, 30, 35, 40, 45, 50, 55, 60, 70, 80. Other sizes available include 06, 08, 10, 90, 100, 110, 120, 130 and 140.



Gutta percha points in 25 and 60 mm lengths. These are available in the same sizes and dimensions as the paper points and files.

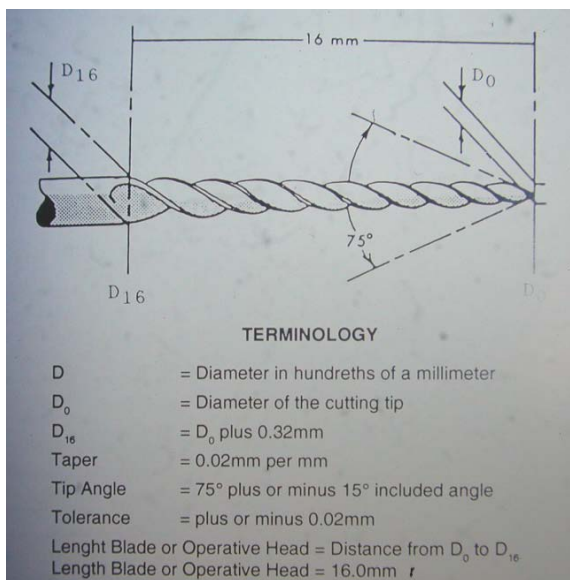
-a variety of sealer/cement products and delivery systems

-all the equipment, instruments and materials for restoring the access holes and other coronal damage

Now we will look at the steps involved. Be aware that I am going to outline this in very basic terms and that there are a number of variations based on the specifics of the case and operator preference. There is almost always more than one way to do everything.

Access

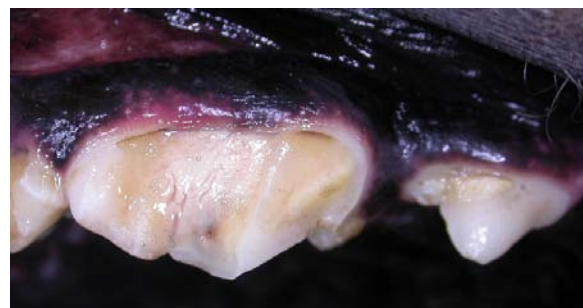
Step one in the process of performing root canal treatment is to gain access into the root canals. The key is straight-line access to the apex of each root. This is particularly important when using relatively inflexible stainless steel files as they do not like to follow a curved path. There is a paper in the Journal of Veterinary Dentistry Volume 10, Number 4 from December of 1993 (Manfra Marretta, Golab et.al) on Ideal Coronal Endodontic Access Points for the Canine Dentition.



-a variety of lengths and sizes of sterile paper points

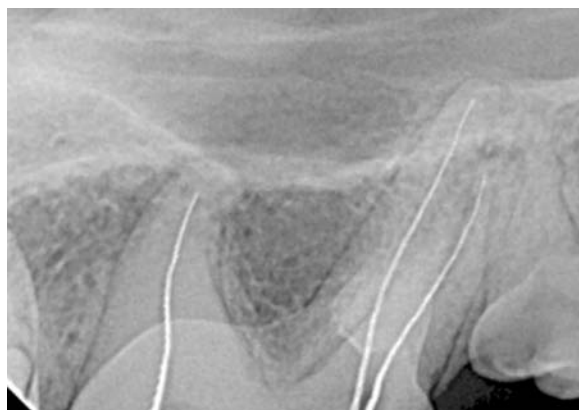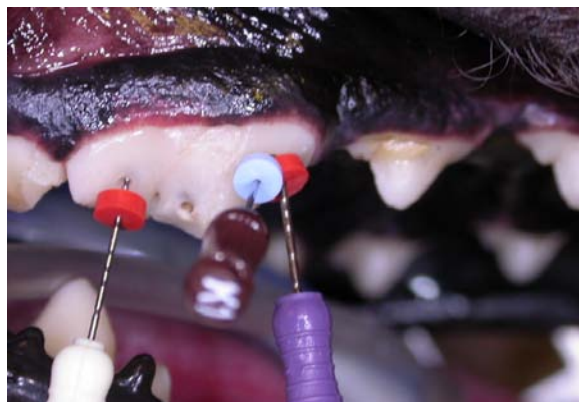


-a variety of lengths and sizes of gutta percha points



A right maxillary 4th premolar tooth with pulp exposure and necrosis. After detailed examination, I decided that this tooth was a good candidate for root canal treatment.

With the advent of nickel-titanium, power-operated systems such as the LightSpeed System, we can take a few more liberties with the location of the access points on some teeth in order to place the hole in a location where it will not have as much impact on the strength of the tooth. But we still need to be able to pass the instruments all the way to the apex (floor of the root canal) in a relatively straight or very gently curved line.



The fracture site which exposed the pulp did not give access into any of the three canal, so two more holes had to be created to get into the canal. The photo shows the files in place with the rubber stops against the tooth. The radiograph confirms that each file has reached working length.

Instrumentation

Once the access hole(s) has been created, the next step is to navigate to the very end of the canal in each of the roots. Depending on the size of the canals, this may be very easy (large canals) or very challenging (narrow canals). We start with a small-diameter instrument and place it into the canal until we think it has reached the apex and then take a radiograph to determine if

we have or have not reached the apex. If the end of the instrument is where we want it, we place the rubber stop on the file against the tooth at the access site, then remove the instrument and measure from the stop to the instrument tip to determine the working length. This is the distance each subsequent instrument must reach in order to be filing right down to the end of the canal. In a large dog's canine tooth, the working length is typically between 37 and 42 millimeters and hence the need for 60 mm long files.

The instruments used to debride and shape the canal are cylindrical. Most of them are tapered (narrowest at the tip and getting wider up towards the handle). They are numbered according to the diameter of the tip in 100ths of a millimeter, so a #50 file is 0.50 mms in diameter at the tip. The smallest file in the 60 mm length (for large canine teeth) is a #15. In the 25 mm long files (for smaller teeth, we can get files as small as a #06 (0.06 mms at the tip).

Starting with the first file that is able to reach the apex, and moving up through the instrument set with each file being just a wee bit larger than the previous file, the canal is debrided and shaped to create a gently tapering cylindrical cone. Between instruments, long, narrow needles are used to inject irrigants into the canal to flush out debris (pulp remnants, dental shaving), decontaminate the canal space and act as a lubricant for the files. Irrigants can include EDTA (softens dentin and removes the so-called smear layer), a chlorhexidine solution or sodium hypochlorite (bleach).

This is a repetitive and sometimes tedious part of the treatment. File, flush, next file, flush, next file, flush... until - well the end point is determined in a variety of ways and to some degree depends on the shape and size of the canal at the beginning of the procedure.

The goal of instrumentation is to remove all remnants of the pulp tissue, to remove all other debris that has found its way into the canal space, to decontaminate the canal space and to create a canal shape that will allow for complete obturation of the space in 3 dimensions.

Irrigation

Irrigation goes on throughout the instrumentation phase but then more irrigation happens at the end of instrumentation.

Anytime an instrument of any sort is dragged across a dentin surface (on the outside or on the inside of a tooth), a smear layer is developed. This is a layer of organic debris from the dentin itself. This smear layer partially blocks the dentin tubules and makes it hard for liquids to contact the dentin and penetrate into the tubules. If the pulp has undergone septic necrosis, then it is assumed that the dentin tubules have been colonized with these bacteria and we want to get rid of as much of these bacteria as we can.

Instrumenting the canal will scrape away some of the contaminated dentin lining the canal but will also produce a smear layer. During instrumentation, irrigation may alternate between EDTA (to remove the smear layer) and bleach (to penetrate into the dentin tubules and kill bacteria).

Following instrumentation, the canal should be flooded with EDTA again to remove the smear layer and then irrigate copiously but carefully with bleach. The old method involves 'positive pressure' irrigation in which the irrigant is instilled down into the canal through a long needle and then it flows back up the canal and out the access hole. This method sort of works but can actually pack debris under hydraulic pressure, down into the apex and/or if there is an air bubble at the apex, the irrigant may not reach all the way down. Also there is a risk of extruding bleach through the apex into the periapical space and this can have catastrophic results.

A newer method, under the brand name "Endo-Vac" used negative pressure (suction) to draw the irrigant down the canal from the access hole to the apex and then back up and out through the needle. This system has been shown to be more effective in removing debris from the canal.

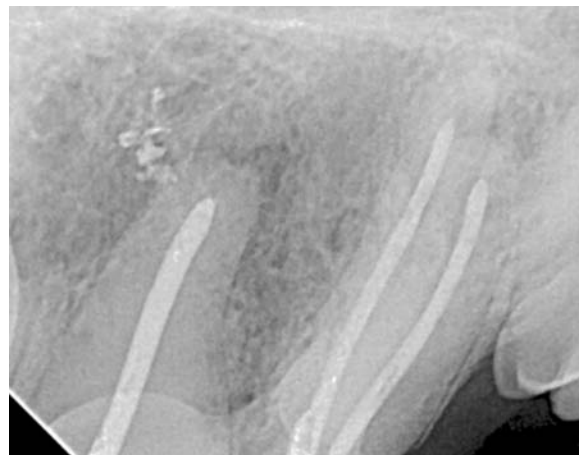Once the smear layer has been removed with EDTA and the canal has been decontaminated with copious lavage with bleach, the bleach needs to be rinsed out with copious lavage using sterile saline. Then the canal needs to be dried

and this is done with absorbent paper points placed into the canal to soak up any residual fluid.

Obturation

With the canal(s) instrumented/debrided and thoroughly flushed and dried, it is time to start filling them. The goal here is to completely fill the empty space within the tooth and to seal all of the ramifications of the apical delta(s) so any bacteria remaining inside the tooth cannot get out through the apex and any fluid in the periapical periodontal spaces cannot get in and stagnate.

Obturation involves placement of a solid bulk filling material in conjunction with a sealer-cement to act as an interface between the dentin wall of the canal and the solid material.



Here is a different right upper 4th premolar tooth with the canals obturated. Some of the sealer/cement has been extruded through the apical delta of the distal root. A small "apical puff" like this is desirable as it indicates that the apical delta channels have been filled. These canals were instrumented with the LightSpeed™ system, which creates non-tapered cylindrical canals.

Many materials have been tried over the centuries and research continues in an effort to find the ideal combination of ingredients and materials. At time of writing, the mainstay of obturation materials is gutta percha which is a natural rubber compound. This rubber is mixed with zinc oxide, radiopacifiers and plasticizers and then formed into tapered points to match the shape and size of the files used to instrument the canal. Though gutta percha only makes up 20%

of these points by volume, they are referred to as gutta percha points.

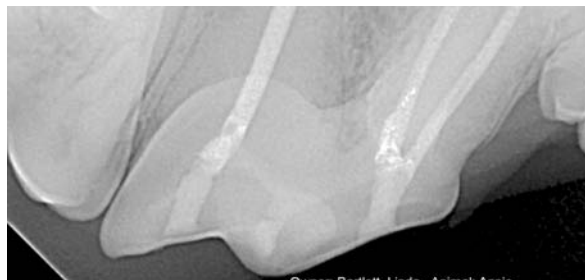A small amount of sealer-cement is instilled into the canal to the apex to coat the entire wall of the canal, then a gutta percha point the same size as the last file used is inserted into the canal to push the cement into the apical delta channels, open dentin tubules and any other little nooks and crannies that the solid point does not fill. The next phase, which can sometimes go very quickly and sometimes takes a lot more effort, is known as condensation. Basically, using a variety of instruments and techniques, the gutta percha is tightly packed into the canal(s) and more gutta percha is added until no more can be squeezed in. Radiographs are taken throughout this procedure to monitor progress.

Once the canals have been thoroughly obturated as confirmed by radiography, it is time to move on to the restorative phase.

Restoration

Among the primary goals of coronal restoration is the creation of a hermetic seal to prevent oral bacteria from gaining access to the pulp chamber. At a minimum, this involves filling all of the access holes with a bonded composite restoration. Now we are into a whole other discipline known as operative or restorative dentistry. This will require the purchase and reading of more text books, attendance at more lectures and labs and the acquisition of more material, instruments and equipment.

When doing root canal treatment of a multi-rooted tooth, I like to fill the chamber within the crown as well as filling the access holes.



This view shows the restorations in the access holes and throughout the chamber within the crown.

After Care

As endodontic treatment is far less invasive and traumatic than extraction, the need for post operative analgesia is greatly reduced. If the pulp was already necrotic at presentation the procedure did not disrupt any live tissue at all. If the pulp was still vital, the tooth would have been more sensitive pre-op (with an exposed vital pulp) than post-op (no exposed nerves). Therefore, providing there was no other invasive oral surgery, I typically will rely on the long-acting pre-op local anesthetic (bupivacaine) and a post-operative dose of NSAID (meloxicam) to give about 24 hours of post-operative analgesia.

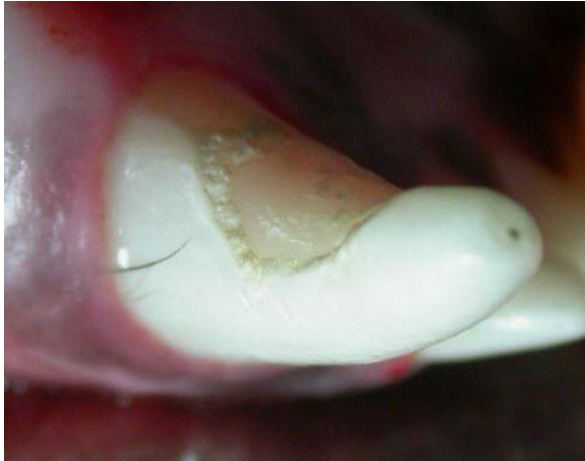Again, providing there were no other invasive oral procedures at the time of the root canal therapy, there are no soft-tissue wounds to heal and so the patient can go home and have their normal diet with no need to soften it. Owners can return to tooth brushing (or start working on the program to train their pet to enjoy tooth brushing) the next day. There is no need for restricted activity post-operatively other than as needed to give the patient time to regain strength and co-ordination after their anesthetic.

I hardly ever use antibiotics of any sort, but, if the pre-operative radiographs revealed significant apical lucencies, I am inclined to send home clindamycin 11mg/kg BID for 10 days. The root canal procedure will have removed the source and portal of entry for the bacteria, but it cannot reach into the periapical space to decontaminate those tissues. Periapical lucencies indicate chronic periapical infection so I will give antibiotics to clear that up.

Some discussion and counseling about appropriate chewing behaviours is typically indicated. Teeth do not fracture spontaneously. If the fracture was the result of a freak traumatic incident then simply trying to avoid further traumatic incidents in the future is all you can do. If the fracture was the result of inappropriate chewing behaviours, then these behaviours need to be modified or further damage to the treated tooth and all of the other teeth is very likely.

Canine teeth often suffer damage from "cage chewing" in which the animal is grasping cage/crate bars or chain link fence with their

canine teeth and wearing the teeth down on the distal surfaces.



Typical 'cage biter' damage to the distolingual aspect of the lower right canine tooth. Without changes to this dog's behaviour and/or environment, the future for this canine (and the others) is not bright.

If the tooth was fractured/damaged by chewing on hard or abrasive objects, then the patient must be prevented from chewing on such objects in the future or more trouble is almost certain to develop. Natural mammalian bones of all types including all antlers, hard nylon and plastic toys, hard-pressed and large rawhide toys, dried cow hooves, ice cubes, rocks, tennis balls (very abrasive!) are all to be avoided.

The knee cap rule states, if you would not want me to hit you (or your dog) in the kneecap with the item, do not let your dog chew on it.

What about a cast metal crown to protect the tooth from further damage? I have some colleagues who feel that every tooth that has had root canal treatment must have a cast metal crown placed. I feel that few, if any treated teeth need cast metal crowns. The truth likely lies somewhere in the middle. But that is a discussion for another day. All I will say is that a cast metal crown may offer some protection for that one tooth, but it does nothing to protect any of the other teeth, and so environmental and behavioural modifications are still required.