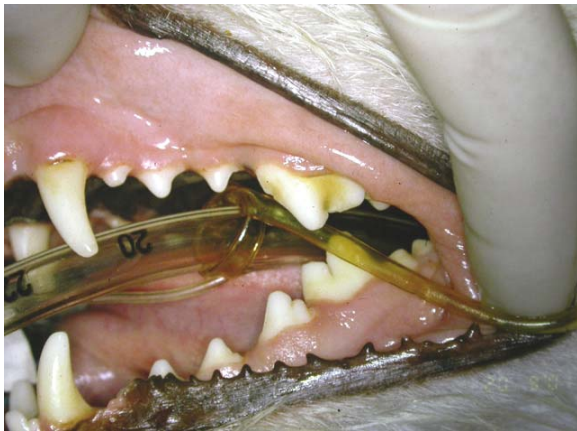

PERIODONTAL DISEASE: OUTTA SIGHT!

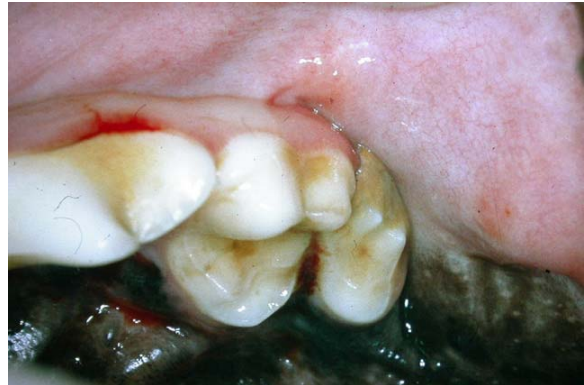I touched on this issue in The CUSP back in 2005 (<http://www.toothvet.ca/PDFfiles/PerioCommon.pdf>) but would like to revisit it and add some illustrative images to drive the point home. As always, before starting a discussion on periodontal disease, I want you to review periodontal anatomy and physiology: (<http://www.toothvet.ca/PDFfiles/PerioAnat&Physio.pdf>.)

The point I want to get across in this piece is that periodontal disease absolutely cannot be properly or fully appreciated in a conscious dog or cat because the problem is located below the gingiva, hidden from view. As an example, in the photo below of a four-year-old Jack Russell Terrier, there is at least one tooth with end-stage periodontal disease that requires extraction.



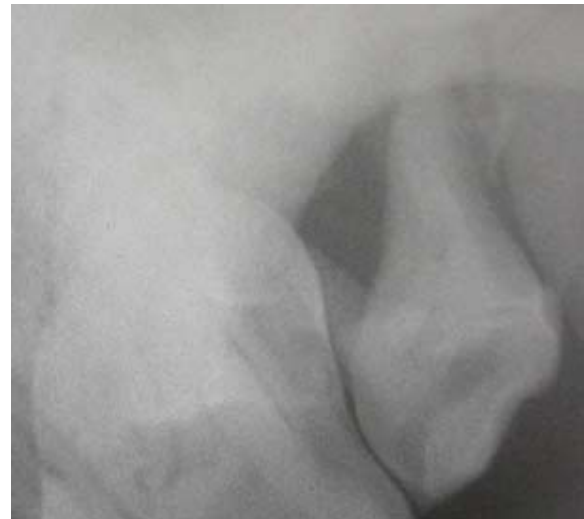Looking at this photo, you can see some very minor calculus accumulations on the crowns of some teeth while some other teeth look perfectly clean. The gingiva is a nice, healthy-looking pink colour, there is no evidence of gingival recession or discharge from below the gum line, but I promise you, you are looking at at least one hopelessly diseased tooth. Care to guess which one? Care to place a wager on your guess? I suspect that most of you, seeing this mouth in the front office at vaccine time would assess it as healthy and move on to the rest of the examination.

This was a good little dog and he allowed me to have a thorough look in his mouth. I always do these examinations with my headlight and surgical telescopes on so I can see into all the dark corners of the mouth. On conscious examination, I was able to see this:

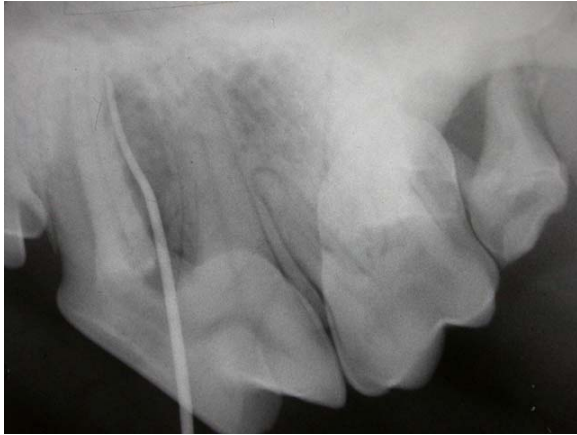

The left maxillary second molar has a lot of calculus on the buccal (cheek) side and while this may or may not be a problem, I was not able to see the gingiva back there and so was concerned that this tooth might be in trouble. That was the impetus for getting Taz admitted for a COHAT. On the other hand, this tooth was not visible in the first photo I showed you so this is not the tooth I was referring to earlier.

I expected the second molar to be in trouble and as you can see on the radiograph below, it is.

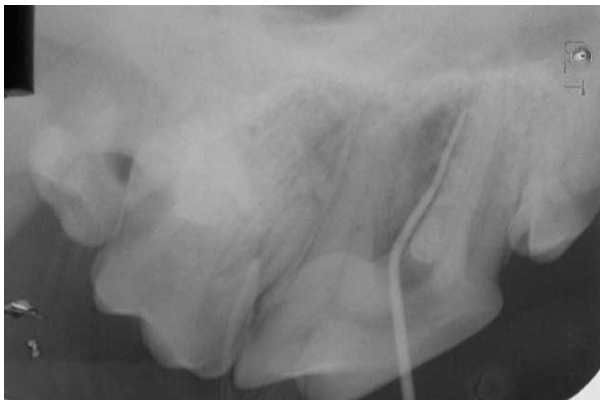

There is virtually no (zero, nil, nothing) in the way of bone support remaining for any of the three roots of this tooth. It has over 90% attachment loss and needs to be extracted. Though the calculus on the crown hinted that this tooth might be in trouble, I was still surprised to see how extensive the damage was. But this was not the big surprise. In the next image, the second molar is to the far right.



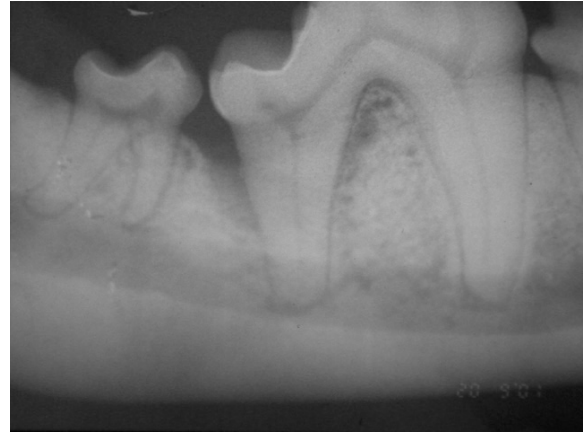To the left, we see the fourth premolar. The linear density is a soft, rubber probe (gutta percha point) placed into the periodontal pocket around the palatal root of this tooth. The probe extends about 85% of the length of the palatal root and so we have about 85% attachment loss.

In theory, I might have amputated this one diseased root and done root canal treatment on the other two to save the tooth. However, the problem was bilateral and the owners did not have the financial resources to allow for that option. Here is the radiograph of the right caudal maxilla:



We see the same, deep palatal pocket as well as dramatic bone loss around the second molar roots.

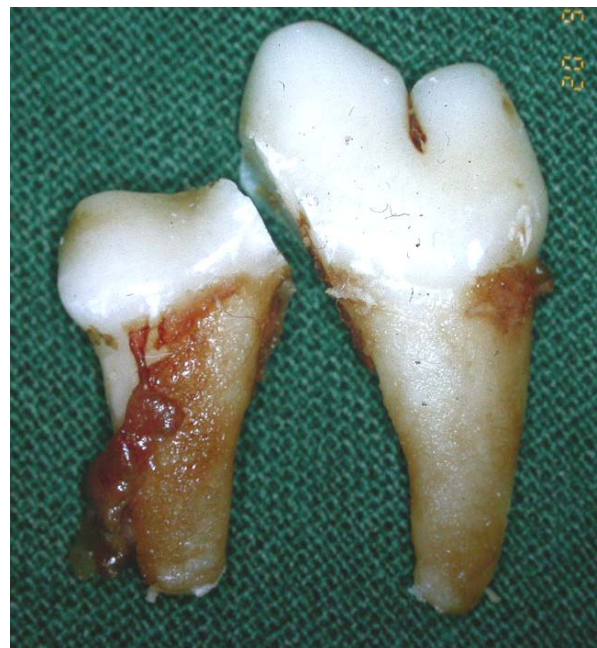Below these teeth, the right mandibular first molar was in trouble as well.

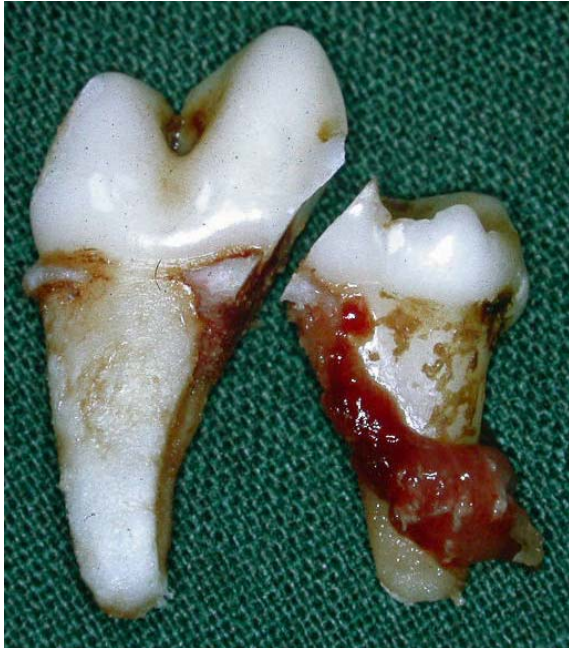

Down the distal aspect of the distal root of the first mandibular molar there is an infra-bony periodontal pocket that extends well over 50% of the length of this root.

If this had been the only problem in Taz's mouth, this molar would certainly have been treatable. I would have reflected gingival flaps, debrided the root surface and removed all the inflamed soft tissue from the pocket, might have placed a bone grafting material and then closed the flaps back over the defect. However, since the upper fourth premolar and molars were being extracted, there was no point in doing advanced periodontal surgery to save this lower molar, so I extracted it as well.

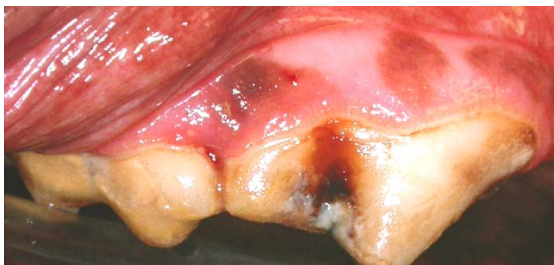
The following photos are of the extracted molar as seen from the buccal side and then from the lingual side.



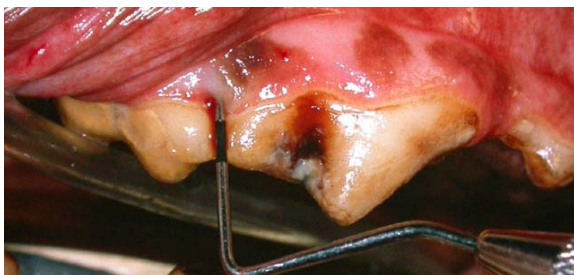

In both of those views we can see some mineral deposits on the distal root as well as the inflamed soft tissue that occupies an infra bony periodontal pocket. If there is to be any chance for these types of periodontal defects to heal all of this soft tissue must be removed. It is not enough to just remove the plaque and calculus from the root surfaces.

On the next page is another photo I use in my lectures to make the point that most periodontal disease is completely hidden from view.

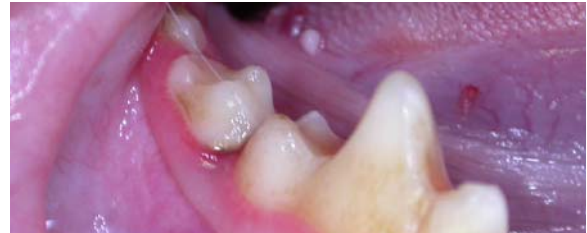

In this photo of the right upper fourth premolar and first molar tooth, we see some calculus and staining on the crowns and some mild, marginal gingivitis. Overall, everything looks pretty darned healthy – until we use the periodontal probe and find...

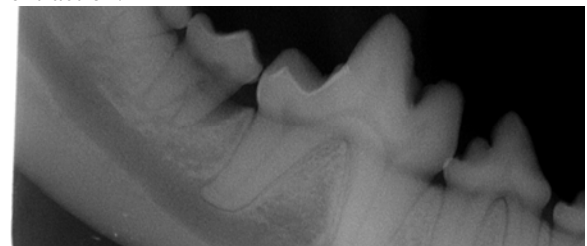


that there is a 9-mm deep periodontal defect between these teeth. This is an old photo and I never did make a digital copy of the radiograph. Never-the-less, the point is clear. The vast majority of periodontal disease is hidden from view, even in the anesthetized patient. To find and assess periodontal lesions, you must probe and explore around every tooth and take intra-oral dental radiographs.

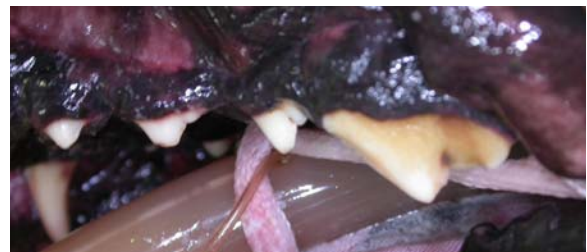Here is another one. There is a hint of some subgingival calculus on the mesiobuccal aspect of the second molar in this photo.



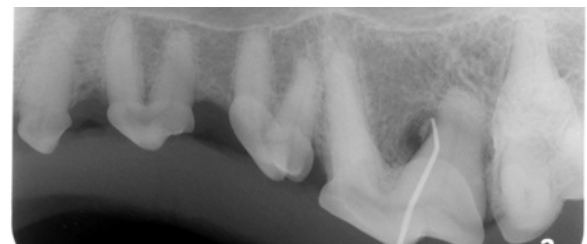The radiograph shows a very deep, infra bony pocket extending 90% of the root length, ie, end-stage periodontal disease and a tooth that requires extraction.



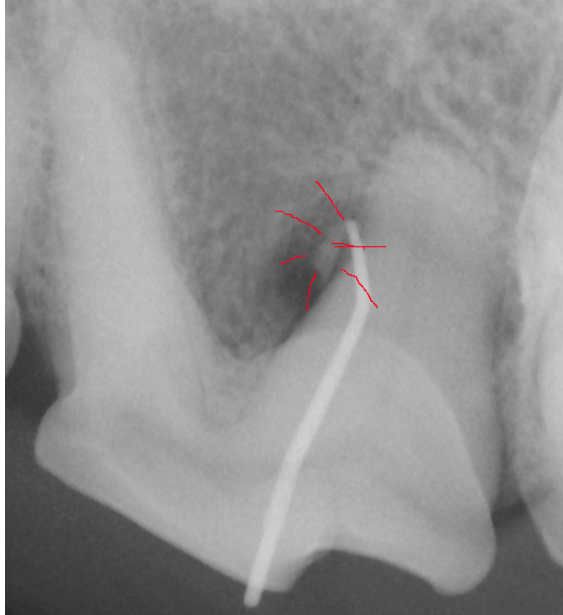
And one more example, this time another left upper fourth premolar tooth. Again, just a little coronal calculus but nothing to hint at the defect hiding below until we probe and radiograph...



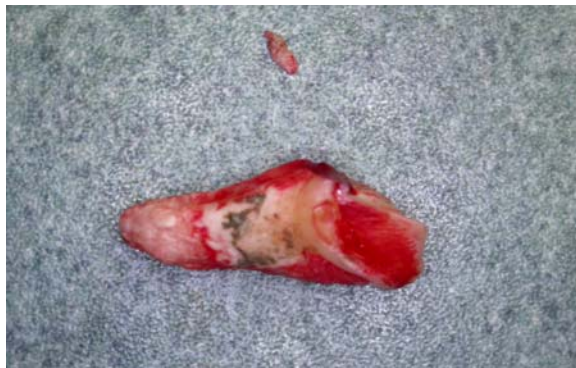and see a periodontal defect encompassing almost the entire distal root of the tooth – requiring extraction.



In this instance it appears as if the periodontal defect was incited by the impaction of a foreign body; likely a splinter of a bone the dog had been chewing on – another reason to NOT give dogs bones of any sort to chew on.



And here is the extracted root, showing the palatal side, along with the fragment of foreign material.



The important message is that if you wait until you can see obvious evidence of periodontal disease on a conscious exam before starting to recommend treatment, you have waited way too long and the animal has been suffering in silence, probably for years.

❖ Sam Low, a human periodontitis, provided the Key Note address at the 2008 Veterinary Dental Forum. He was a very entertaining speaker who has a good grasp of the similarities and differences between human and veterinary dentistry. Among his key messages were the following:

- periodontal disease is 30% bugs and 70% host response. By this he means that while the periodontal pathogens are a necessary trigger for the development of periodontal disease, it is the host's immune/inflammatory reaction to the pathogens that causes the majority of tissue destruction. While controlling the bacterial population in the mouth and below the gum line is important, managing the patient's response is also very important. The host response is probably genetically determined. This explains why some patients can manage in the face of complete dental neglect while others need very aggressive periodontal management programs. Each periodontal program needs to be tailored to the patient.

- Dr. Low's three (facetious) secrets of success in periodontal practice

1. *Move every three years.* This comment reminds us that even with best efforts, patients with a high susceptibility to periodontal disease will deteriorate over time. If you and your periodontal patients are together for many years, you should expect that problems will develop over time no matter how diligent you and the owners are.

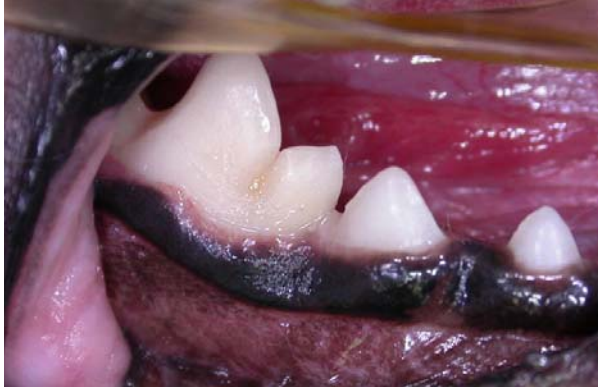2. *Extract all posterior teeth (premolars and molars).* Here he is telling us that as long as these teeth are in the mouth, they are at risk of periodontal disease and will require diligent care and monitoring – we can never let down our guard when managing periodontal disease.

3. *Extract the remaining anterior teeth (incisors and canines).* The only way to 'cure' periodontal disease is to extract all the teeth. Once all the teeth are gone, you can relax but until then, every tooth in every periodontal patient requires a life-long maintenance plan. This includes daily home plaque-control strategies and regular professional monitoring and maintenance therapy.

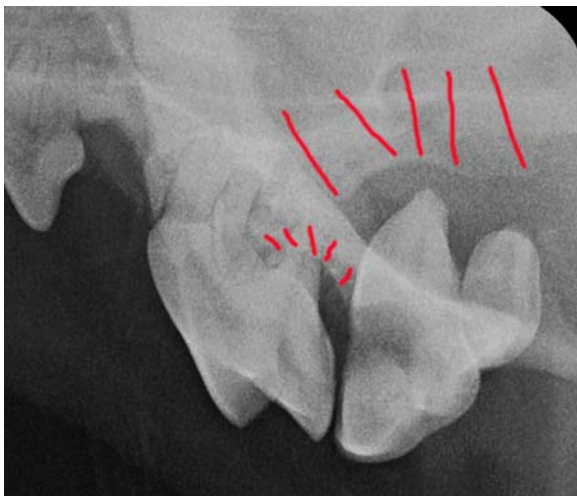
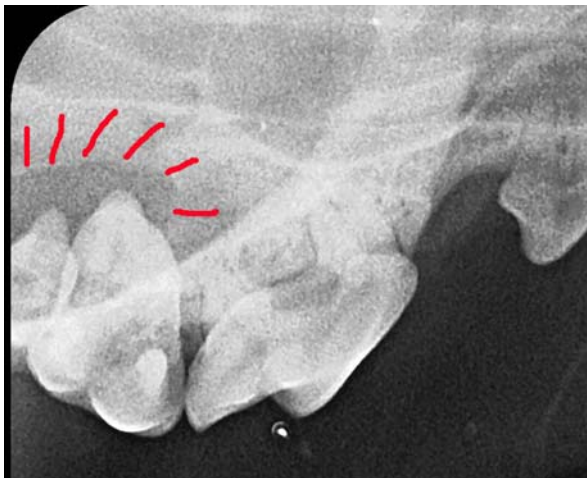These three rules got a good round of laughter from the audience, but there is a large grain of truth to them all. A good example of the results of ignoring this were seen here just this week...

I saw an eight-month-old micro-poo (1.6kg) in August of 2004 to remove some retained primary canine teeth. At that time I also did some selective extractions to reduce crowding and improve the periodontal future for the teeth left in place. My discharge notes to the owner and letter to the referring veterinarian both stated plainly that this dog would be very prone to periodontal disease. I recommended t/dTM, daily tooth brushing and annual COHATs. Well this little un-neutered male refuses to allow home care. They have been feeding t/dTM but he was

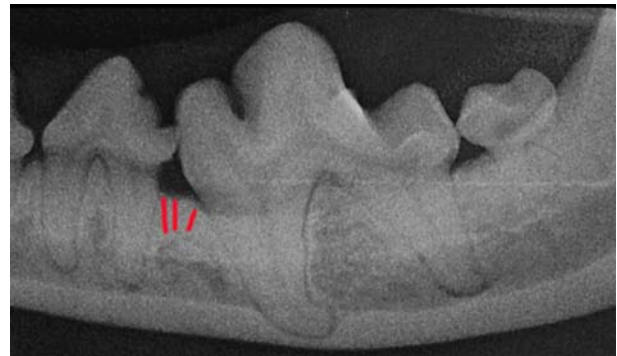
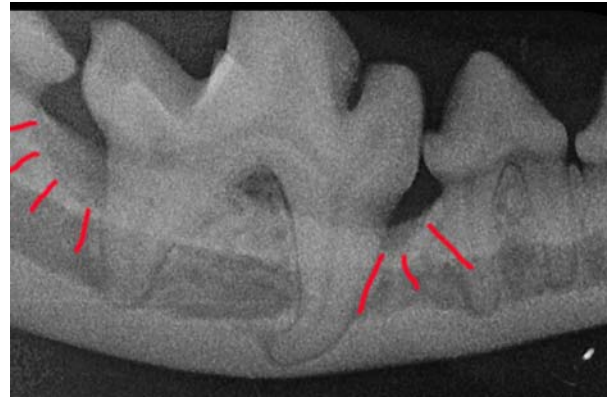not presented for his first dental treatment until this fall (three years later than my recommendation). When the rDVM removed calculus from the crowns, it was apparent that more than a cleaning was needed and so the dog was sent my way again. Because he had just had his teeth cleaned, the clinical photo looks pretty good.



The radiographs, however, tell a different story:



There is complete loss of the bone around the upper first and second molars on both sides as well as end-stage periodontal disease along the distal root of the left upper fourth premolar tooth.



There are deep infra-bony pockets mesial and distal to the right lower first molar (the area that looks good in the photo) and a suggestion that the same thing is about to get started mesial to the left lower first molar.

In the end, I extracted a total of eleven teeth that were well beyond salvage. I did periodontal surgery with placement of a synthetic bone graft around the lower right first molar as well as some open root planing in a few other areas. Now we have to see how this patient can respond to that treatment.