

This informational page is an attempt to describe a complex subject in limited space. It should be considered to be very introductory. More in-depth discussions of this and many other subjects can be found on the Old CUSP Articles page at www.toothvet.ca. You are encouraged to visit and make use of the resources there and elsewhere on my website.

Periodontal Disease is Hidden

Dogs and cats (like most mammals) have four *periodontal* tissues. These are the tissues that surround and support the teeth and are responsible for keeping oral bacteria from getting at the bones that the teeth stick out of.

Cementum is a thin layer of tissue that covers the root(s) of the tooth.

Alveolar bone is the part of the jaw bone that makes up the wall of the sockets that the roots sit in.

The *periodontal ligament* is the soft tissue that attaches to the alveolar bone and the cementum to hold the tooth in place and act as a shock absorber for the tooth.

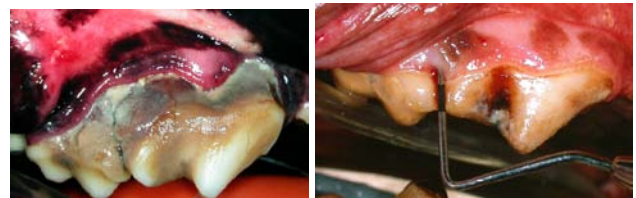
The *gingiva* or *gum tissue* is the only periodontal tissue we can see in the healthy situation and it forms a seal around the top of the root to keep bacteria from getting at the other periodontal tissues.

If *plaque* (an invisible slime of bacteria) is allowed to form and remain on the teeth, it causes inflammation of the gingiva and this inflammation weakens the attachment of the gingiva to the cementum and bone. Now the bacteria can get below the gum line and grow there, causing more inflammation and more tissue destruction. As the disease progresses, the bacterial toxins and the patient's inflammatory response lead to progressive loss of bone, increasing pocket depth and sometimes gingival recession.

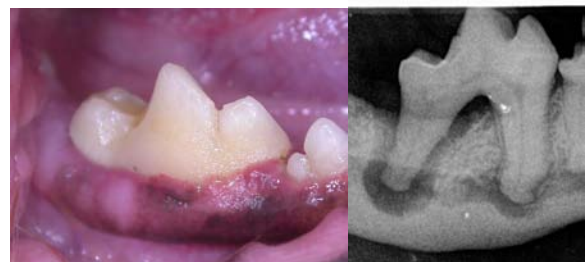In the conscious patient, we can see the crowns of the teeth and can assess how much *tartar* (mineralized plaque) is on the crowns of the teeth. But it is not the deposits on the crowns that cause periodontal disease. It is the deposits below the gum line that cause the problems. We cannot see how much plaque and tartar there is below the gum line or how deep the pockets are or how much bone loss there might be without anesthetizing the pet.

In some cases of periodontal disease, there is significant loss of gum tissue (gingival recession) and we can see this in the conscious patient. Even when we see this, we cannot know how much more periodontal disease there is below the surface. So what do we do about this?

We must get your pet under general anesthetic so that we can probe, explore and examine below the gum line around each and every tooth. We also need to get intra-oral dental radiographs to evaluate the bone and root structures. Only by doing this detailed examination can we arrive at an accurate assessment of your pet's periodontal situation. We need this detailed evaluation to begin developing an appropriate treatment plan for your pet.



Left: Lots of gingival recession at the right upper 4th premolar and 1st molar making it very obvious that there is end-stage periodontal disease. Right: No recession or inflammation visible and not much tartar on crowns, yet there was a 9mm deep periodontal pocket between these teeth.



Superficially, everything about this lower 1st molar looks great. Below the surface there is end-stage periodontal disease at the distal root as well as septic pulp necrosis with bone loss at the tip of the mesial root.