

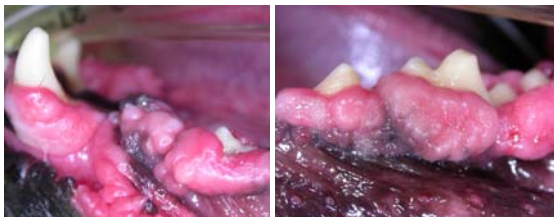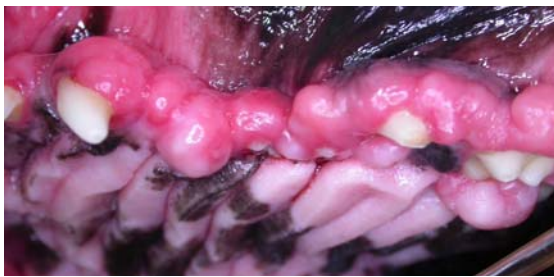FOCUS ON: GINGIVAL HYPERPLASIA

For a problem that is so common, there is really not very much in the veterinary literature on this odd condition, so it seems time for me to tell you a bit about my understanding of gingival hyperplasia, what brings it about, why it is a concern and how we manage it.

As with all of these “Focus” articles, I will try to give reasonable detail, but it will still end up being an introductory-level article, because there are just so many variations and factors to consider. I would encourage readers to visit the “Old CUSP Articles” page at www.toothvet.ca to review the article on [periodontal anatomy and physiology](#) before reading any further. Also, within the year, there should be a new textbook from Elsevier Publishing on oral and maxillofacial surgery (edited by Frank Verstaete) and it will cover this in much greater detail.

Gingival hyperplasia refers to the pathological growth of excess or redundant gingival tissue as a result of an increase in the number of cells. By contrast, *gingival overgrowth* refers to an increase in gingival volume due to an excessive accumulation of extracellular matrix proteins.

In gingiva hyperplasia, the tissue is histologically basically normal (other than usually being inflamed) or may contain islands of dystrophic calcification or bony metaplasia but it is not considered a neoplasia. Of course, the distinction between a benign neoplasia of gingival origin and hyperplasia of gingiva is at times fuzzy and arbitrary. This is in contrast to the

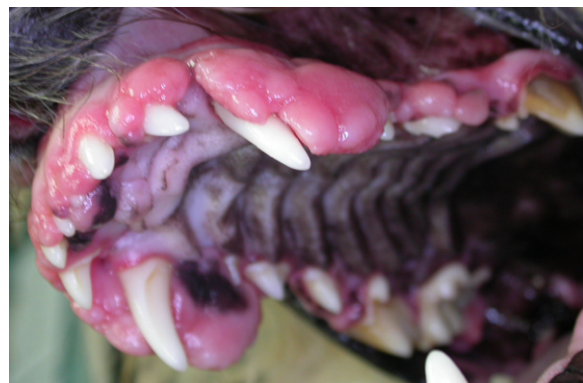

Left maxillary and mandibular views of an eight-year-old boxer dog with typical presentation of generalized gingival hyperplasia.

various epulide tumors which are true neoplasias arising from the *epithelial cell rests of Malassez* within the periodontal ligament space.

There are some breeds that are reported to be predisposed to idiopathic, generalized gingival hyperplasia including the collie, Great Dane, Dalmation and Doberman. In my practice, boxers are by far the most commonly affected, though one of my most dramatic cases in the past few years was in a wheaton terrier. There is a paper about several other boxer problems ([Focus on Boxers](#)) also on the Old CUSP Articles page but I ran out of room before I got to hyperplasia when writing that article.

We do not know why boxers (or others) develop this exuberant gingival over-growth, but one theory is that it is their way of reacting to gingival



Pre-op view of the maxilla of a five-year-old Wheaton terrier with generalized idiopathic gingival hyperplasia.

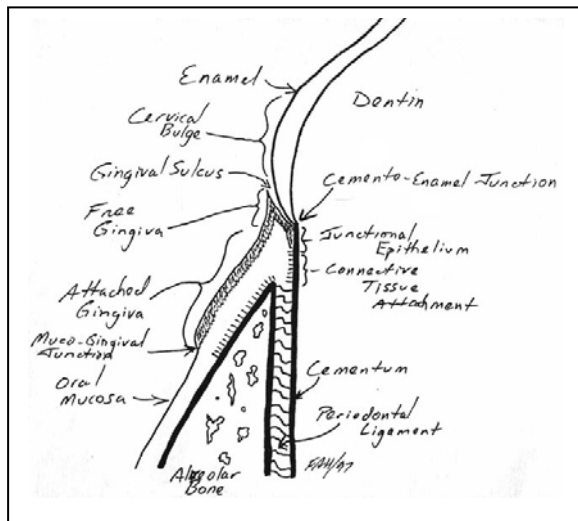
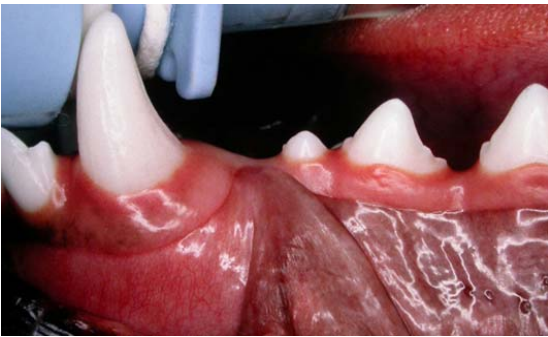inflammation. Rather than getting gingival recession, they get hyperplasia.

There are several drugs that have been associated with gingival overgrowth (the increase in matrix protein form of enlargement) including phenytoin derivatives, calcium channel blockers and cyclosporine. Watch out for this last one. With a decrease in sales of cyclosporine in human medicine (as better drugs have become available for human use) and the recent licensing of this drug for use in dogs in Canada, we can expect to have this drug marketed to us very aggressively. Therefore, I expect cyclosporine use to increase dramatically in Canada over the next few years and with this increased use, I expect to start hearing about many cases of drug-induced gingival overgrowth.

Since gingival overgrowth is a drug-induced increase in extra-cellular matrix proteins, the treatment is based on discontinuing the offending medication if at

all possible. Once the drug is withdrawn, the gingival overgrowth will typically regress. In some cases, the gingiva will return to normal height and contour with no further treatment required. In others, some enlargement may persist and surgical gingivoplasty may still be indicated.

If you have done as I suggested and reviewed the article on periodontal anatomy and physiology, you will recall that the *free gingival margin* should taper to a knife-sharp edge and that it should be about 0.5 to 3 millimeters coronal to the *cemento-enamel junction*. Here is a photo and drawing of that:



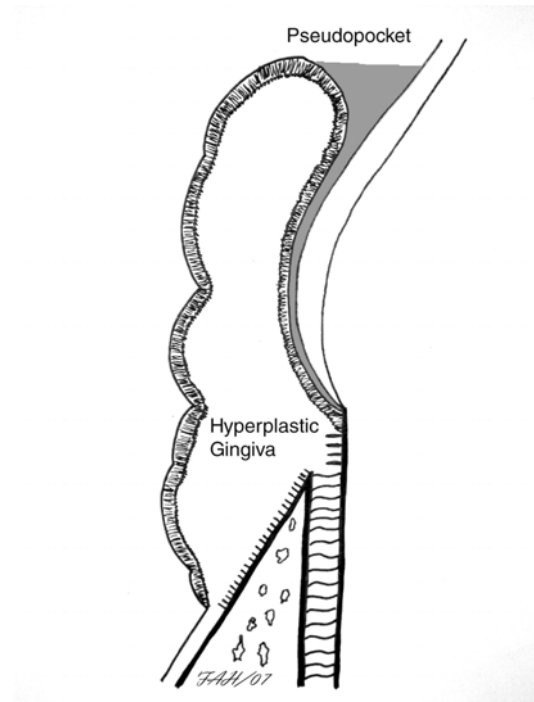
Since the gingiva does not attach to the enamel but lies against, there is a potential space between the gingiva and the enamel known as the *gingival sulcus*. If the gingiva is healthy, the free gingival margin is not only very thin, it is also firmly braced against the enamel by dense collagen fibers and it is tucked under the *cervical bulge*. In this situation, debris (hair, food, woodchips...) coming along the crown will be deflected away from the sulcus rather than being forced into it.

At the bottom of the gingival sulcus, the (relatively weak) *junctional epithelium* is attached to the root

cementum for a few millimeters and then this gives way to the (much firmer) *connective tissue attachment* of the gingiva to the cementum and the outer surface of the alveolar bone. The body wants to maintain these three zones (sulcus, junctional epithelium, connective tissue attachment) in a relationship termed *biologic width*. Keep this in mind for later when we look at treatment of gingival hyperplasia.

As the free gingiva becomes inflamed (reaction to dental plaque on the crown of the tooth), it starts to become edematous and collagenase starts to break down the stiff collagen fibers in the free gingiva. The rounded free-gingival margin starts to fall out of contact with the enamel opening up the potential space of the gingival sulcus to create an actual space. This makes it easier for debris and bacteria to enter the sulcus, resulting in more inflammation...setting up a downward spiral.

In those predisposed to hyperplasia, the free gingiva starts to grow up the crown of the tooth (coronally) as well as growing in thickness. Even if the attached gingiva remains attached right at the cemento-enamel junction, the sulcus becomes much deeper and so it becomes a *periodontal pocket*. In this case, as the increase in pocket depth is due to the coronal migration of the free gingival margin (rather than the apical migration of the floor of the pocket) it is referred to as a *false pocket* or a *pseudopocket*. Diagrammatically, it might look like this:



This pseudopocket is a wonderful trap for hair, food, and of course, bacteria. Chewing and brushing cannot reach into these deep spaces and so the advantage is given to the periodontal pathogens and periodontal disease is likely to ensue. Inflammation in the depths of the pseudopocket leads to loss of gingival attachment, destruction of alveolar bone and periodontal ligament (so the addition of a true periodontal pocket as the level of attachment migrates toward the apex of the root). This increased risk of developing periodontal infection and irreversible tissue loss is one of the reasons that gingival hyperplasia and gingival overgrowth needs to be addressed.

Another way in which gingival hyperplasia or overgrowth becomes clinically significant to the patient is seen when the enlargement becomes extreme. In advanced cases, the patient cannot close his/her mouth without chewing on the redundant/hyperplastic tissue. Even before this occurs, chewing on food and treats may cause the loose flaps of gingiva to be traumatized. The result of this trauma – pain!

As the ever-expanding gingiva is present as a constant force, it can actually result in the movement of teeth, sometimes all but pulling teeth out of their sockets.

With the problems arising from the redundant gingiva (false pockets, trauma, orthodontic tooth movements), the condition definitely needs treatment. The first step is to determine if the patient is on any medications that might be causing a drug-induced gingival enlargement. If the patient is on one of those drugs, get it off.

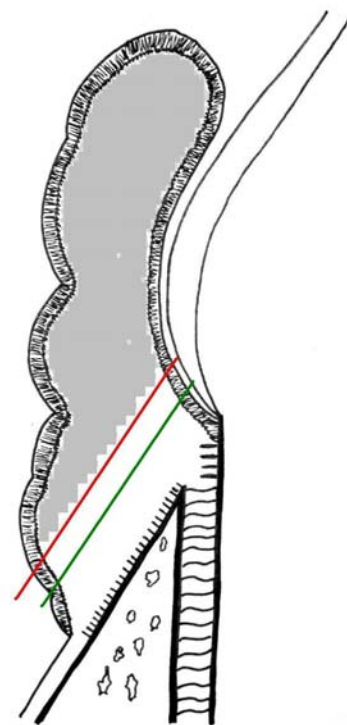
If there is no history of being on any of the suspect drugs, and the problem is generalized (surrounding many if not all teeth in a fairly symmetrical fashion), then you are likely dealing with idiopathic gingival hyperplasia and surgery will be required.

In the photos on page two there is lots of redundant gingiva both in its height and its thickness. Treatment is aimed at recontouring this gingiva back to normal height and contour. We are trying to re-establish normal and healthy gingival architecture.

The first step is whole-mouth intra-oral dental radiographs to assess the status of the teeth and bones hiding below all this excess tissue. Especially in boxers, with their brachycephalic dental crowding, it is common to find extensive periodontal disease, particularly around the premolars. Teeth with advanced disease will need to be extracted.

The next step is to determine the appropriate level for the incision around the teeth that are going to stay in the mouth. We want to remove enough gingiva without removing too much. The literature describes probing to the bottom of the pocket to note its depth, then removing the probe and laying it on the outside of the gingiva with the tip at the level of the bottom of the pocket. Then the tip of the probe is driven into the outer surface of the gingiva at that level to create a bleeding point. This process is repeated every 2-3 mms around the tooth to create a dotted line of bleeding points that outline the location of the pocket depth and then this can be used as a guide for the excision line. I do not like this method, because if there is a true pocket as well as a false pocket, the surgeon may end up removing too much gingiva and exposing furcations of multi-rooted teeth.

The goal in gingival recontouring is to shape the gingiva back to normal height and thickness. We want the new free-gingival margin (after healing) to be 1-3 mms coronal to the cemento-enamel junction so that the body can re-establish the normal biologic width. Depending on the modality used for resection, the surgeon should anticipate a post-operative retraction or loss of tissue during healing. This may amount to as much as 1 millimeter. Therefore, the level of the incision should account for this.



In the diagram above, the red line indicates the beveled angle and location of the incision and the

shaded tissue is that which is to be removed. This incision reduces the depth of the pseudo pocket and also recreates a thin free-gingival margin that is located beneath the cervical bulge but above the cemento-enamel junction. During healing, the tissue will retract to the level of the green line leaving the patient with normal gingival architecture.

If the pocket extends beyond the cemento-enamel junction, that is a true periodontal pocket and requires periodontal surgery that is aimed at preserving and regenerating periodontal tissues. We do **not** reduce the depth of true periodontal pockets by removing gingiva. Only the pathologically increased and redundant gingiva is removed.

There are four modalities used for the removal of the excess gingiva and all have their applications and limitations, fans and detractors.

The simplest and most available technology is cold-steel in the form of a scalpel blade or a gingivectomy knife (Orban or Kirkland). As the excess gingiva is typically quite firm and may contain islands of osseous metaplasia and since the blade will contact the tooth surface when it has cut through the hyperplastic gingiva, blades will dull quickly and require frequent replacement (for scalpels) or sharpening (for gingivectomy knives). As well, since the gingiva has an excellent blood supply, cold-steel excision tends to be a very bloody procedure. Digital pressure with saline-soaked gauze on fresh incisions will help establish hemostasis. While time-consuming and bloody, cold-steel technique is least likely to cause collateral damage to surrounding tissues. On the other hand, the pressure needed to force the blade through tough gingival tissue can make fine control of the shape and depth of incision difficult.

Another 'cold' technique involves the use of twelve-fluted carbide burs in a high-speed dental hand-piece with a cooling spray of water directed at the bur tip as it cuts through the tissue. This method is somewhat faster and can allow for more accurate sculpting of the tissues but does require more equipment. Also, if the surgeon is not very careful, as the bur penetrates through the soft tissue it may contact and damage the hard tissues (enamel, cementum or bone) beneath.

Those who own a laser (CO₂ Nd:YAG, diode) seem to think it is a good choice for gingivoplasty. Reported advantages of laser surgery include sealing of the blood vessels during incision to maintain hemostasis and a clear field of view. The incision is also sterilized by the action of the laser (though the cut surfaces in an oral environment will soon be contaminated regardless). However, laser

gingivoplasty is more time consuming, can increase healing times through the creation of the char layer and there is a considerable risk of collateral damage to surrounding hard and soft tissues. Several human and veterinary references recommend against the use of laser for gingival surgery.

My preferred modality for gingivoplasty is radiosurgery. Radiosurgery is essentially electrosurgery but the frequency of the electrical current is within the radio frequency range (3.0 to 4.0 megahertz) which is higher than regular electrosurgical units. The higher frequency means that there is less lateral heat dissipation into the surrounding tissues and used at an appropriate power setting, there is less thermal necrosis along the incision than with lower-frequency units and maybe even less than with laser. Radiosurgery is reported to result in less scar tissue formation than with laser. It is also far less expensive.

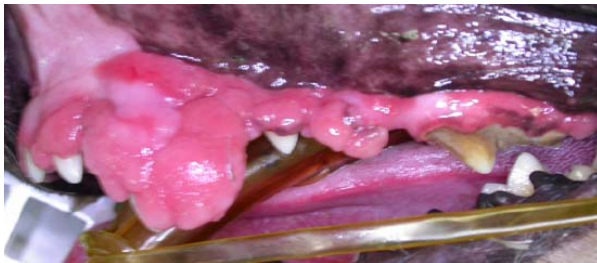The Ellman™ unit pictured provides various wave-form options (pure cutting, cutting with coagulation, straight coagulation and fulgration modes) at 3.8 MHz. I perform gingivoplasty using the filtered (pure cutting) or the rectified (cut/coagulation) wave form. This allows the electrode to pass through the tissue without any pressure applied to incise the tissue while cauterizing small blood vessels as it cuts. The result is a clean, smooth, easily controlled and bloodless incision.



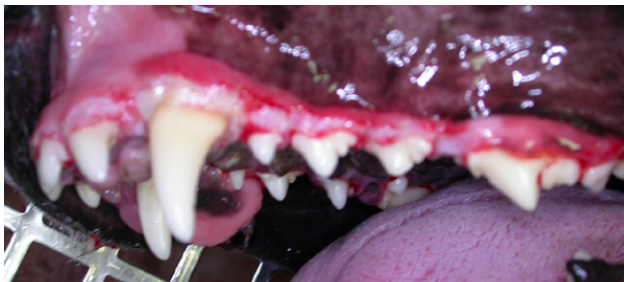Below is a diagram of some of the available electrode tips (taken from the Ellman™ website). When sculpting gingiva, I tend to use the triangle loop as it allows me to plane the tissues flat while still being able to reach into nooks and crannies with the triangle corners.



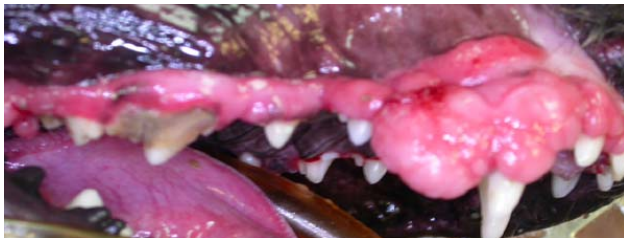My initial incision is a debulking cut to coarsely remove much of the redundant tissue and increase visualization of the underlying tooth. Then I make refining incisions gently removing small amounts of tissue at a time to bring the gingival margin to within a millimeter of the desired target height. For that Wheaton shown earlier, the left side went from this:



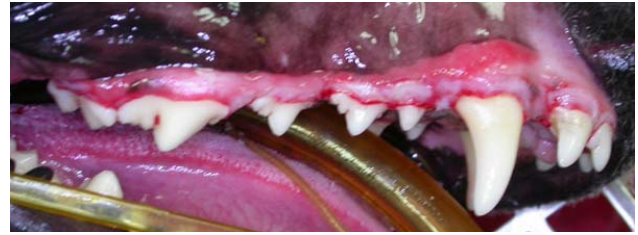
To this:



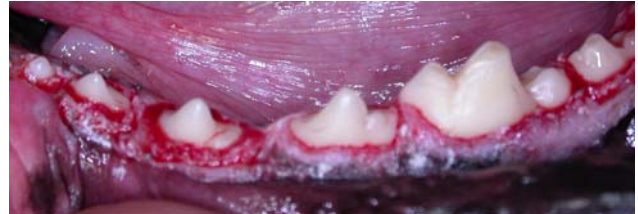And the right side went from this:



To this:



The left mandible in the eight-year old boxer on page 1 looked like this post-op.

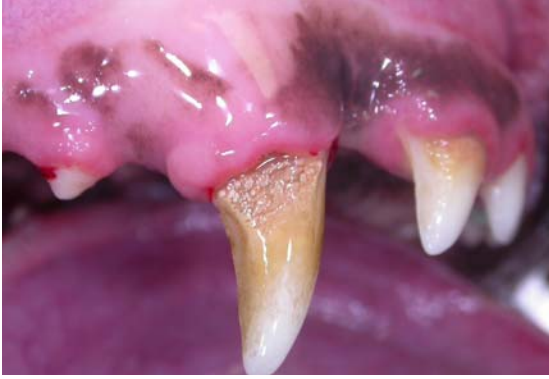

While the incised tissues do blanch a bit immediately after the cut, they 'pink-up' again within minutes.

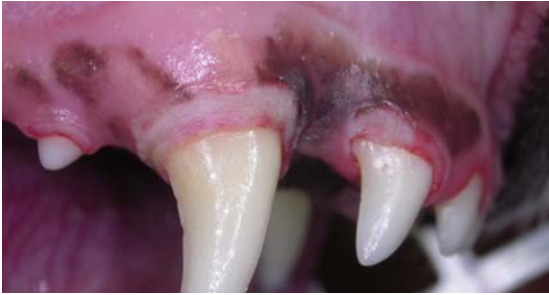While the Ellman™ Surgitron™ is a powerful tool, like all powerful tools, it is not without its risks. Just as you can take your fingers off faster with a power saw than with a hand saw, so can you cause serious tissue damage by careless use of radiosurgery. The power setting should be adjusted to the lowest setting that will allow the electrode to pass through the tissue without 'drag'. The electrode should be kept on the move rather than allowing it to rest in one spot while active, as this would allow greater dissipation of heat into the surrounding tissues. The incision should be kept well away from bone and contact with the tooth avoided.

Analgesics such as NSAIDs and narcotics should be dispensed for several days post-operatively. The patient should be fed a softened diet and hard toys and treats withheld for two weeks. The owners should suspend any home care (tooth brushing) during the healing period as well. Once the gingiva has re-epithelialized (7 to 10 days), owners should return to, or start working on a daily plaque-control program. The theory is that in patients predisposed to generalized gingival hyperplasia, keeping the teeth clean and the gingiva healthy may delay the recurrence of the hyperplasia and increase the time before surgical debulking becomes necessary again.

As well as the dramatic, generalized gingival hyperplasia shown at left, some animals will present with smaller, localized lesions such as this:



Which can be treated in the same manner:



And in two weeks it will look like this (different patient but same owner, problem and treatment).

