

ENDODONTICS

Endodontics is that branch of dentistry that deals with the internal anatomy of the tooth and the area where the inside of the tooth communicates with the rest of the body.

Teeth are composed of four main tissues. The crown is covered by a thin veneer of *enamel* and the root is covered by a thin layer of *cementum*. Under the enamel and cementum is *dentin* and inside the dentin is a chamber filled with soft tissues known collectively as the *dental pulp*. The chamber within the crown is called the *pulp chamber* and within the root it is called the *root canal*.

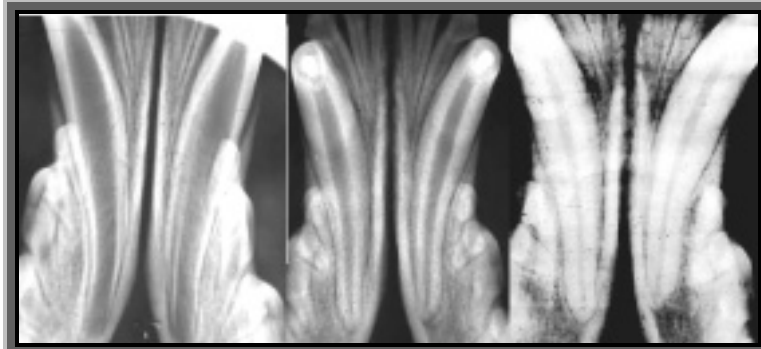
The pulp is a highly organized collection of tissues that includes blood vessels, nerves, lymphatic channels, undifferentiated cells and highly specialized cells (it gets a forty-page chapter in Urban's *Oral histology and embryology*). The pulp can become diseased in a number of ways, but they all boil down to inflammation (usually due to infection) or avascular necrosis (usually due to trauma).

ENDODONTIC ANATOMY & PHYSIOLOGY

When a permanent tooth is developing within the jaw of a young animal, it is constructed from the outside in. That is to say, the enamel of the crown is produced early in the process so that the outside dimension of the crown is established early. Once the enamel is formed, the tissue that made it goes dormant and no more enamel can ever be produced for that tooth.

Inside the tooth is the pulp. Lining the inside wall of the developing tooth is a single layer of low columnar cells known as *odontoblasts*. These cells produce the dentin. During pre-eruptive development and during eruption, the odontoblasts produce *primary dentin*. Once the tooth has developed to its final length, the odontoblasts produce *secondary dentin* such that the pulp chamber inside the tooth gets smaller as the wall of the tooth gets thicker. This progression can be seen in the series of radiographs, all of the same animal and taken at 6, 14 and 32 months of age.

There is another form of dentin known as *tertiary, reparative or irregular dentin*. If there is a chronic but low-grade stimulation of the odontoblasts, they may respond by producing dentin at an accelerated rate. This is an attempt to create a thicker buffer zone between the pulp and the noxious stimulus. Once the pulp has retreated sufficiently from the stimulus, tertiary dentin production ceases. The tertiary dentin is structurally less organized than primary and secondary dentin and has a much darker colour.



In the first radiograph (six months of age), the teeth are still erupting, the dentin walls of the crowns and roots are very thin and the apices (root tips) have not yet formed. At 14 months, the teeth are fully erupted, the apices have closed and the dentin walls in the roots and crowns are much thicker than at six months. (The canine teeth have had crown reduction with pulp capping for orthodontic reasons). By 32 months, the pulp chambers are smaller still and the root walls thick enough for these teeth to be considered 'mature'. As long as the pulp remains healthy, the odontoblasts will continue to produce secondary dentin and the pulp chambers will get progressively narrower as the animal ages.

In dogs and cats, after the apex is ‘closed’, there are still several tiny channels through which the pulp communicates with the rest of the body. This collection of channels constitutes the apical delta. This is the only way into or out of the tooth – there is no collateral circulation.

Dentin is porous. This is a crucial point to keep in mind as it has great impact on the effects of various dental injuries on the pulp.

The photo-micrograph shows a clean, freshly cut dentin surface. In human teeth, each mm² of freshly cut dentin has 40, 000 open pores. These pores are the hollow lumens of the *dentin tubules*, which make up the bulk of the dentin. Ultrastructurally, the dentin is made of a collection of hollow tubules packed tightly together with *intertubular dentin* filling the spaces between the tubules.

Another point that is very important to understand is the intimate relationship between the odontoblasts and pulpal nerve fibers and the dentin tubules. As the diagram (lifted from Orban’s *Oral histology and embryology*, 11th ed., Mosby Yearbook, 1991) shows, there are

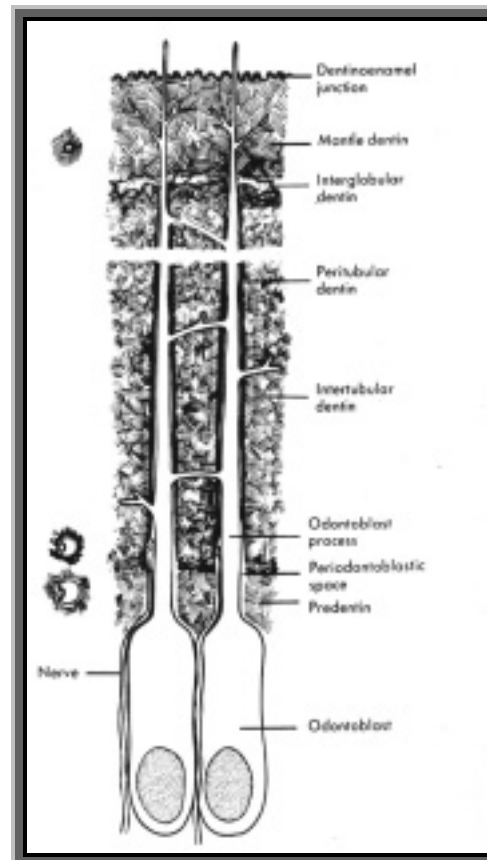
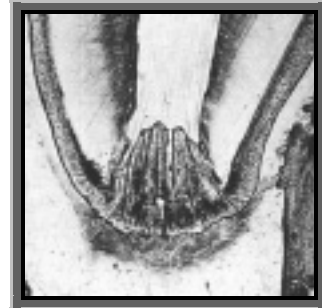
cytoplasmic extensions of the odontoblasts that run through the dentin tubules to the dentin-enamel or dentin-cementum junction. There are also nerve fibers lying alongside the *odontoblastic processes* within the tubules. I want you to keep this relationship in mind, as it is key to understanding a number of endodontic concepts.

The nerves in the pulp can respond to various stimuli (heat, cold, pressure, osmotic fluid movement, chemical irritation...), but regardless of the stimulus, the sensation registered is pain!!

Now let’s look at endodontic disease, how it occurs and its significance to the patient.

CROWN FRACTURE WITH PULP EXPOSURE

When the crown of a tooth suffers a significant fracture, there is often obvious *pulp exposure*. What I mean by obvious is that the hole is large enough to be seen with the naked eye and you would be able to place the tip of a dental explorer into the pulp chamber through the exposure. When this has occurred, there has been significant trauma to the pulp in that an entire section of this organ has been torn away from the tooth. The remaining pulp is now exposed to the outside world and is, therefore, exposed to mechanical, chemical and bacterial insult. As with any open wound, pulp exposure causes pain.



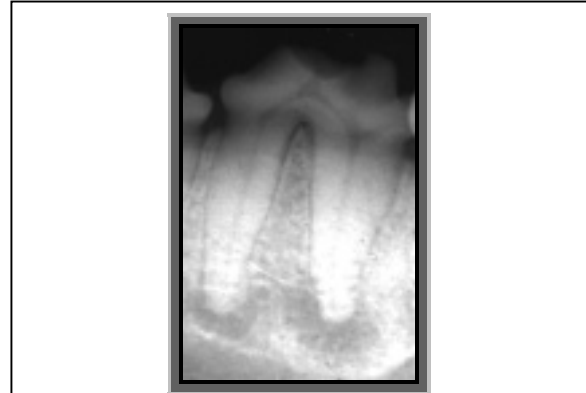Exposed pulp will *always* become inflamed, just as any damaged tissue will – it has no other choice. What happens next and in what time frame is variable, but the end result is always the same. The pulpitis will become irreversible as the pulp succumbs to bacterial infection and the pulp will die.

As the pulp is dying, there is the intense stabbing pain that some of us know personally as “tooth ache”. Once the pulp is dead (days/weeks/months), the pain subsides (dead tissue sends no signals). Now the pulp chamber is filled with necrotic soft tissue and bacteria – a really good culture medium. The bacteria and their toxins will eventually ooze out through the apical delta and into the periapical periodontal space, leading to a chronic, periapical periodontitis, which is painful, but in a more diffuse manner than the pulpitis. As long as the tooth is not being used, it is tolerable, but biting or chewing with this tooth will push it into its socket, placing more pressure on the inflamed periapical tissues. Therefore, the animal is likely to favour this tooth by chewing on the other side of its mouth.

In time, a periapical periodontitis may do many different things. It may develop into a periapical abscess, which is intensely painful until it finds somewhere to fistulate and release pressure. It may develop into a periapical granuloma, which causes a dull chronic pain. It may develop into a periapical cyst, which will be destructive of surrounding structures as it expands. As well, the inflammation may cause external root resorption.

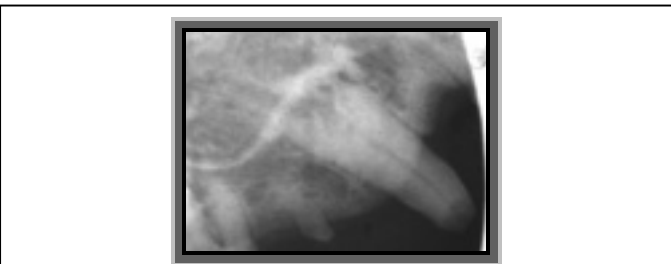Regardless of the specific course the lesion takes, all cause pain to some degree and all are associated with a chronic infection that the body cannot possibly clear. The source of the infection is the bacteria inside the tooth and there is no longer any way for the body to reach in there to clean up the mess. Antibiotics may offer short-term symptomatic relief, **but they have no effect on the source of the infection.**

Most of these lesions will never offer obvious external signs such as facial swellings or large draining fistulae. However, if you think you are seeing broken teeth that are not causing problems, I would say all you have to do is start taking some intra-oral dental radiographs. Then you will see the pathology.



This radiograph of a fractured right mandibular fourth premolar tooth clearly shows not only the obvious pulp exposure, but also the dramatic decrease in bone density (due to chronic osteomyelitis) at the apices of both roots. The tooth was not loose, there was no fistula or gingival inflammation associated with this lesion. The problem is buried deep within the mandible where it can only be assessed radiographically.

Studies published in 1992 concluded that dogs and cats feel pain just like we do. They behave differently than we do – they do not complain. They just carry on because they have no alternative.



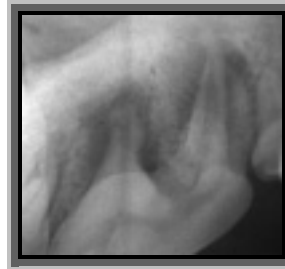This right maxillary canine tooth in a cat has had a chronic pulp exposure, which has resulted in inflammatory external root resorption. The apical half of the root has been destroyed and so conventional root canal therapy was not an option. Again, there was no fistula, facial swelling or gingivitis associated with this lesion. Assessment is by dental radiography.

CROWN FRACTURE WITH NEAR-EXPOSURE

Many teeth suffer crown fractures without an obvious pulp exposure. But, if you consider the porous nature of dentin and the odontoblastic processes within the tubules, you will see that there really is pulp exposure at the microscopic and cellular levels. For one thing, odontoblastic processes will have been severed and so there is cellular damage from the fracture. Also, the open dentin tubules are large enough to act as conduits through which bacteria can gain access to the pulp chamber.

Exposed dentin is sensitive to many stimuli, including heat, cold, touch and osmotic gradients. The current theory to explain dentin sensitivity is known as the *hydrodynamic theory*. It suggests that the pain associated with dentin exposure is due to fluid movement pulling on the odontoblastic processes and the nerve fibers within the tubules. If air passes over exposed dentin, it desiccates the surface, decreasing the surface tension and causing fluid to flow from the pulp toward the surface. Sweet drinks create an osmotic gradient that will also irritate exposed dentin by drawing fluid through the tubules. Anything physically touching the exposed surface decreases surface tension and draws fluid through the tubules. All of these cause pain.

The pain associated with dentin exposure will stimulate inflammation. Inflammation causes vasodilation and edema but since the pulp is constrained in the rigid confines of the pulp chamber, the increased pressure within the pulp will strangulate the venous return and the pulp will die (avascular necrosis). Once the pulp is dead, there is no vital soft tissue occluding the dentin tubules, which become open conduits for bacteria. Now the pulp is not only necrotic, it is also contaminated.



The crown of this right maxillary fourth premolar had a slab fracture with a near-exposure. The pulp has obviously become infected and necrotic, as there is dramatic periapical bone loss due to chronic osteomyelitis.

The bacteria do not really wait for the pulp to die before they start to colonize the tubules. The demise of the pulp is likely due to a number of noxious stimuli working simultaneously, including the initial cellular trauma, hydrodynamic irritation and bacterial contamination.

Teeth with near-exposure do present a bit of a diagnostic conundrum. I have seen a number of fourth upper premolars with very similar looking fractures. Some of them have obvious endodontic disease evident on radiograph and others have no clinical or radiographic signs of endodontic disease. So, unlike teeth with obvious pulp exposures (which have a certain outcome of pulp necrosis), teeth with dentin exposures may or may not survive the injury.

One might ask, “How near is too near for the pulp to survive?” There is no one answer. Many factors are involved, including the age of the tooth at the time of injury, the thickness of the dentin remaining between the outside world and the pulp and host response to the injury. If the injury is recent and you are able to see a pink spot in the fracture site, you are seeing what is referred to as a *pulpal blush*. This means that the dentin remaining between you and the pulp is so thin that the pulp’s pink colour is showing through. These are *very-near-exposures* and will definitely need endodontic treatment or extraction.

An old very-near-exposure will not have a pulpal blush as necrotic pulp is not pink. You may see a dark spot, which is the necrotic pulp showing through the thin layer of dentin. More often, however, the exposed dentin surface will be covered by calculus. The porous dentin is far more

plaque-retentive than smooth enamel and usually the animal will avoid chewing with these teeth. Therefore, plaque and calculus accumulate rapidly on these teeth, obscuring your view of the fracture. At first look, you may not even notice that the tooth has a fracture. That is why you have to look carefully.

MINOR CHIP FRACTURES

Fractured teeth often have more calculus than the other teeth in the mouth. The porous dentin is more plaque retentive than smooth enamel. A fractured tooth is sensitive so the animal uses it less, chewing on the other side of the mouth instead.

Look closely for the subtle signs of dental fractures.

If you notice that the upper left fourth premolar has lots of calculus but the rest of the mouth looks clean, chances are, that dirty tooth has a fracture. Look closely at the shape of the crown. Is it different from the upper right fourth premolar? Usually the tip of the mesial cusp is missing, making the crown look shorter than the healthy tooth.

Teeth frequently suffer minor chip fractures in which the dentin is exposed, but there is still a thick layer between the pulp and the outside world. The tooth is not completely without reparative capacity and will not roll over and die at the slightest insult. So these minor chip fractures usually do not require treatment.

What factors determine if a fracture is a minor chip or a near exposure? A major factor is how close the fracture comes to the pulp. Recall from page 2 that the dentin wall of a tooth is thin when the animal is young and it gets thicker as the tooth ages. Therefore, a fairly minor-looking fracture on a young tooth may come dangerously close to the pulp while the same fracture on a ten-year-old tooth would be insignificant.

When presented with a tooth that has a crown fracture without pulp exposure, you should rule out endodontic disease. This would be so much easier if our patients could talk, but they cannot.

Question the owner about any changes in behaviour, eating or chewing habits. Radiograph the damaged tooth and also radiograph the contra-lateral counterpart for comparison. If the pulp chamber of the chipped tooth is larger than the same tooth on the other side of the head, the chipped tooth has been dead for a long time. Also look carefully at the periapical periodontal space for evidence of widening of the space for bone loss.

WORN TEETH

Some dogs love to chew abrasive things such as rocks, tennis balls or their own fur (flea allergy dermatitis dogs). Some dogs have abnormal tooth-to-tooth contact due to malocclusion and this can cause wear. Whatever the cause, the wear may be significant enough to lead to pulp exposure. This is just like a crown fracture with pulp exposure.

In some instances, the wear on the crowns is gradual and the teeth have time to react. As the wear breaks through the enamel and exposes the dentin, the odontoblasts beneath the worn area are stimulated (via the hydrodynamic theory). This causes these odontoblasts to produce tertiary dentin. So the pulp retreats from the noxious stimulus and leaves tertiary dentin in its wake.

Tertiary dentin is darker than normal dentin. When you look at a worn tooth, you are likely to see the outer ring of enamel, then the off-white primary and secondary dentin and in the centre, a dark spot of tertiary dentin. But how do you tell tertiary dentin from necrotic debris plugging an open pulp chamber? Tertiary dentin is typically reddish-brown, hard and smooth and is shiny even when dry. Debris plugging an open chamber is typically black, it yields when probed with a dental explorer and it is dull looking when dried.

As long as the rate of wear is gradual, the tooth can get worn right down to the gum-line with out ever causing pulp exposure or irreversible pulpitis. However, if the rate of wear is just a bit faster than the rate of tertiary dentin production, eventually, the wear will get too close to the pulp leading to irreversible pulpitis and pulp necrosis. Once the pulp is dead, further wear will break through the previously produced tertiary dentin, resulting in pulp exposure.

So, worn teeth may be all right or they may have endodontic disease. How do you tell the difference? Radiographs, of course.

DISCOLOURED TEETH

It is quite possible (common in fact) for teeth to suffer pulp necrosis without any crown fracture. A tooth that is misaligned and subject to abnormal occlusal trauma will often develop a traumatic pulpitis, which can lead to pulp necrosis. A poorly contoured restoration that leads to abnormal occlusal contacts can have the same result. Ask anyone who has ever had an oversized filling how much discomfort it caused.

Blood-borne infection may colonize the pulp leading to pulpitis and pulp necrosis. This is likely a rare event.

Trauma to the head may disrupt the blood supply to the tooth leading to an avascular necrosis. Bear in mind that the pulp has no collateral circulation. The only way into or out of the tooth is through the apical delta.

Blunt trauma to the tooth may lead to a traumatic pulpitis, leading to pulp necrosis.

Whatever the cause, a traumatized pulp will develop a pulpitis. If the insult is mild, the pulpitis may be reversible and the tooth may survive. If the insult is more serious, the inflammation may become irreversible, resulting in pulp necrosis. As the pulp dies, the endothelium of the blood vessels falls apart releasing red blood cells. RBCs are larger than dentin tubules, but once the RBCs breakdown, the hemoglobin will seep into the dentin tubules and cause intrinsic staining of the dentin. The result is a crown that looks pink/purple. As the hemoglobin degrades, the crown will change to a gray or light brown colour.

Generally, purple/gray/tan teeth have no infection. However, as the pulp tissue degrades, intercellular contents are spilled and these include a host of mediators of inflammation. They will seep out through the apical delta, leading to periapical periodontitis.

TREATMENT PLANNING

This is the easy part. Teeth with endodontic disease or exposure require treatment and there are only two options; endodontic therapy (of some sort) or extraction. The endodontic therapy might be indirect pulp capping, direct pulp capping or total pulpectomy.

Presentation	Treatment Options
Crown Fracture or Wear with pulp-exposure.	Endodontic treatment or extraction.
Crown Fracture or Wear with near-exposure.	Endodontic treatment or extraction.
Chip Fracture or Wear with tertiary dentin.	Radiographic evaluation and possibly endodontic treatment or extraction.
Pink, purple, gray or tan discolouration of the crown.	Endodontic treatment or extraction.