

STOP BRACHYCEPHALISM, NOW!

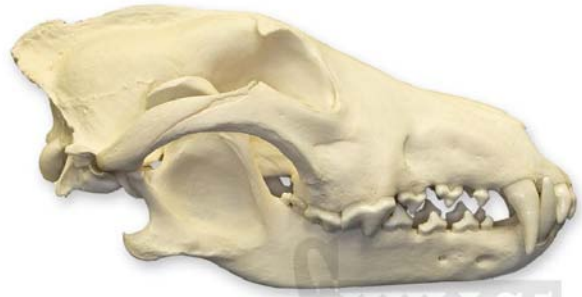Domestication of the dog and cat has been a double-edged sword. By agreeing to come into our homes and lives, they receive food, shelter and companionship as well as medical care when indicated. However, they have also given up the right to choose with whom they reproduce and thus have given up the chlorinating effect that Mother Nature has on the gene pool. As a result, there are many breeds of dog and cat that are so hideously deformed and unthrifty that they would not last a week in the wild. I suspect that representatives from each of the specialty colleges could write a similar paper on the problems they see day in and day out that are a direct result of misguided breeding practices. As a veterinary dentist, I see the results of this in the ways it negatively impacts the oral health of these animals and that will be my focus.

Some breeds are predisposed to certain serious conditions (dobermans and cardiomyopathy, wheatons and amyloidosis, westies and atopy...) but these animals are not intentionally bred to have these conditions. That would be crazy, inhumane, unethical. So why is it that we condone, even promote, the breeding of animal's whose very design has a negative impact on health and quality of life for every single member of the breed? I am referring to brachycephalism.

Before considering the problems that human-directed selective breeding has caused, we need to consider how the oral cavity of the various canine and feline species are supposed to be put together. An easy way to do this is to visit the Mammal Gallery of any natural history museum and observe the craniofacial architecture that is found in the wild (designs that work/survive/reproduce without our help). Or take a virtual field trip to www.skullsunlimited.com and look at their catalogue of wild and domestic dog and cat skulls.

In the canidae, the skull type is mesocephalic with a "scissors" bite. The only place in the mouth that there is tooth-to-tooth contact is between the distal third of the lower first molar and the lower second and third molars

contacting the two upper molars. Nowhere in the mouth is there any tooth-to-soft tissue contact. The teeth are proportioned such that they can line up in proper alignment with sufficient gingiva and alveolar bone to offer good periodontal support.

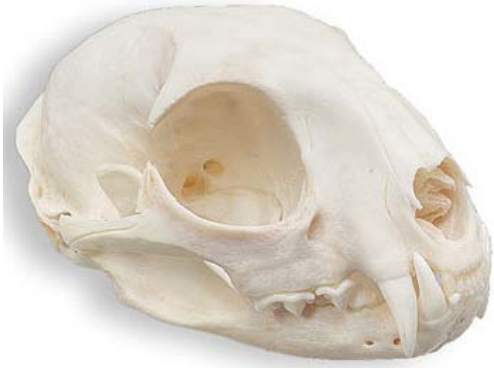

This image of a gray wolf skull was lifted from the Skulls Unlimited web catalogue (as were all of the following dry bone skull images). It shows the desirable craniofacial and dental architecture found in the wild - because it works!

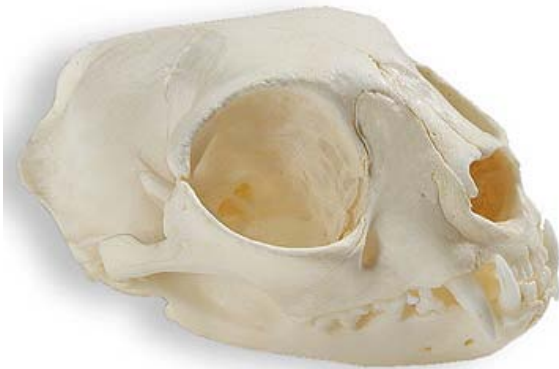

A Labrador retriever skull has much the same anatomy as the wolf.

In the felidae, there may be a level bite with the incisors contacting but often there is no tooth-to-tooth or tooth-to-soft tissue contact at all in these obligate carnivores. Again, the size of the teeth is in proportion to the skeletal frame that they reside in so that alignment is ideal and there is good periodontal support for each tooth.



This image of a bobcat skull shows how a cat head (regardless of the size of the cat) should be put together.

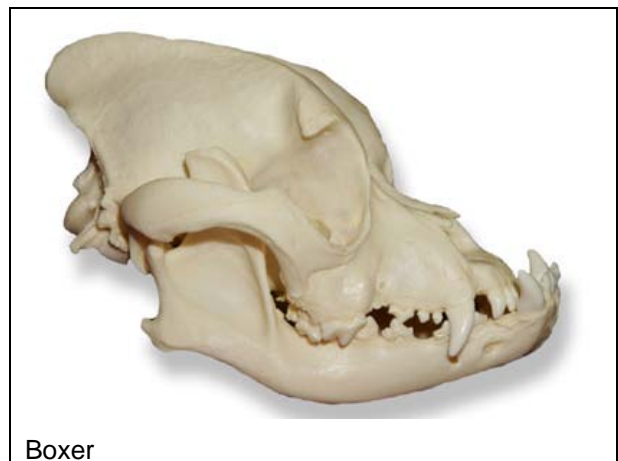
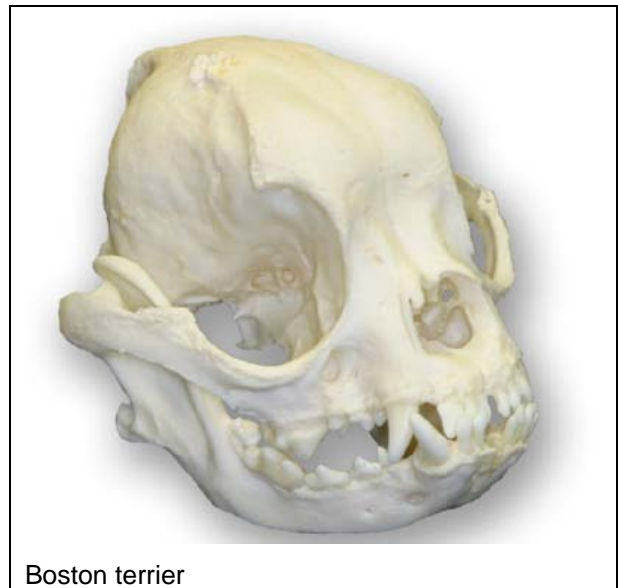
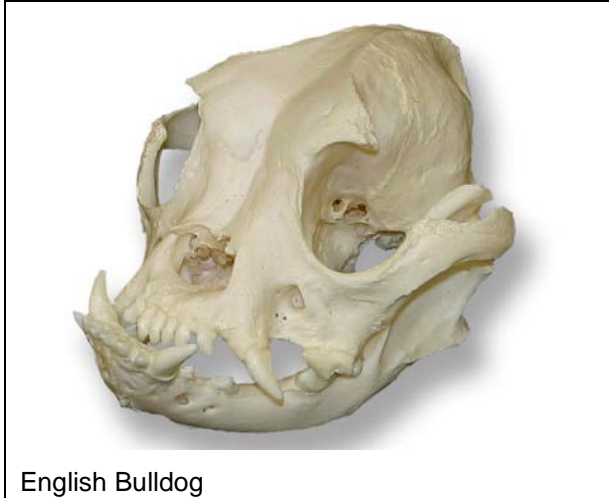The normal domestic cat looks much the same.

In contrast to this functional and desirable design, consider the brachycephalic skull type as seen in so many dog and some cat breeds. Here the maxilla is too short compared to the mandibles (and the mandibles are often also too short for the size of the animal). The upper incisors are in traumatic contact with the floor of the mouth and lower canine teeth. The maxillary premolars are so crowded that there may be no gingiva between and little or no bone support and the teeth may be rotated ninety degrees or more. Some teeth may be under-erupted due to crowding and impaction against adjacent or opposing teeth. The result is that the animal effectively bites itself every time it closes its mouth and there is an extreme predisposition to early onset and rapid progression of periodontal disease. The traumatic contact between the maxillary incisors and the mandibular structures will often lead to traumatic pulpitis and pulp necrosis in the maxillary incisors. There is also

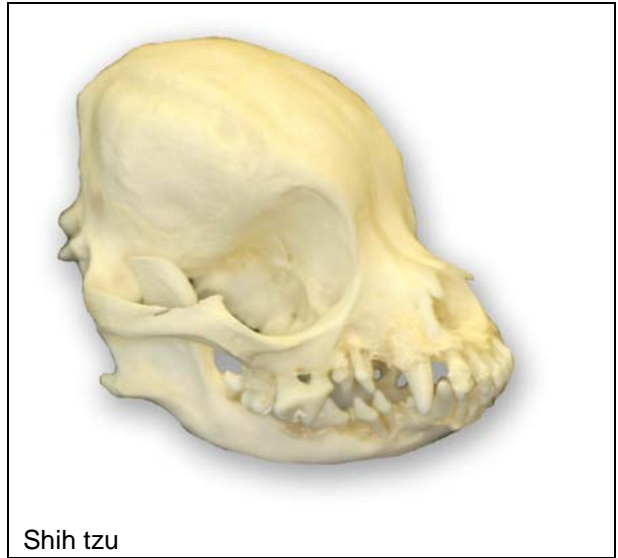often severe bunching-up of the palatal rugae with entrapment of hair, food and bacteria leading to chronic, painful palatitis hidden from view at the bottom of the deep, closed folds.

Some of the dental/oral liabilities associated with brachycephalism can be mitigated by proactive surgery (selective extraction for the most part), but many animals do not get to benefit from these procedures and so live with chronic dental pain and infection.

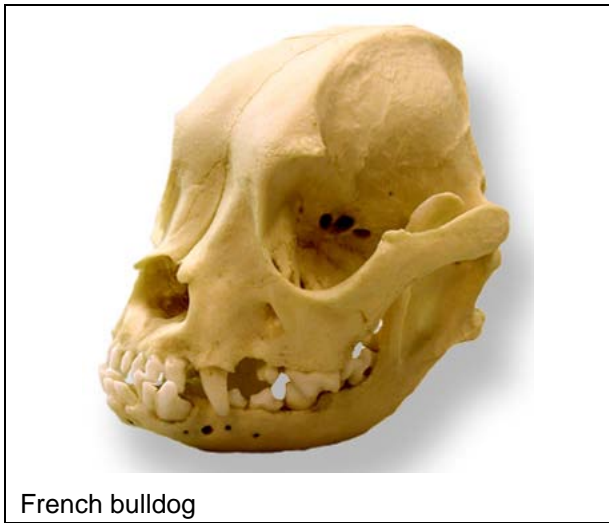




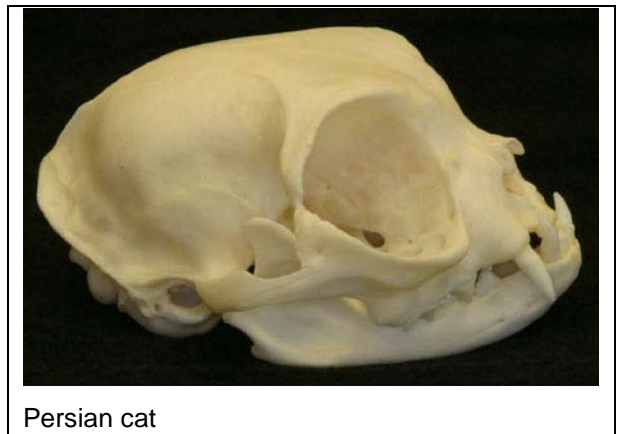English Bulldog



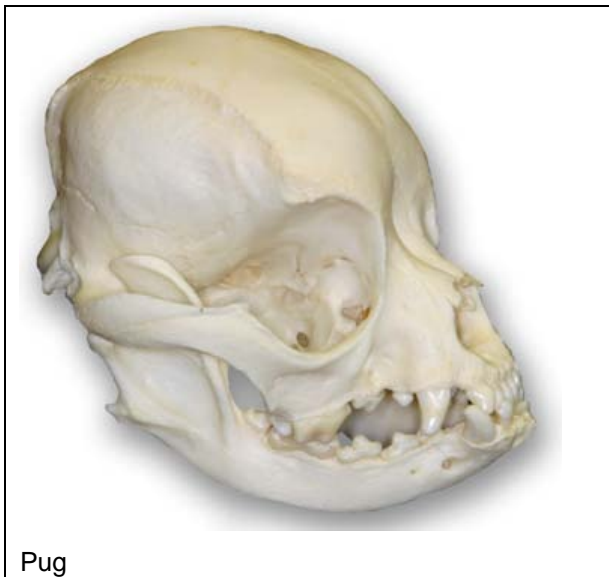
Shih tzu



French bulldog



Persian cat



Pug

In many Canadian jurisdictions, veterinarians have advocated for and achieved a ban on tail-docking, ear-cropping and dewclaw removal as these are considered unnecessary cosmetic procedures that cause (temporary) pain with no benefit to the animals.

- ❖ I believe that as protectors of animal welfare, veterinarians should start a public awareness campaign to inform people of the serious, life-long negative impacts of brachycephalism.
- ❖ I believe we must stop referring to these conditions as "normal for the breed" and refer to them as **"grossly abnormal in accordance with current breed standards"** because there is nothing remotely normal or desirable from the animal's perspective.

- ❖ I believe we must stop using images of these deformed but comical breeds in advertising and promotional materials (such as our websites) as this just increases public demand because they are "so cute" and if you show one on your website you are giving an implied medical endorsement for the suitability of the breed.

I am sure these words are going to stimulate some lively, possibly acrimonious response. I am effectively saying that is it unethical to purposely reproduce animals that are specifically designed to have serious structural deformities simply because the result is considered esthetically pleasing to some people. The extension of this thinking would be to ban a great number of breeds. Oh, the backlash! My word! But when one looks at it strictly from the animal's perspective, there is no valid, logical justification for brachycephalism. Its only positive is that many people find brachycephalic breeds aesthetically pleasing (cute) and that is not a valid excuse for willful perpetuation of these harmful deformities.

What would I like to see happen? Well, we obviously need to provide adequate and appropriate care for the brachycephalic animals currently alive but if I had my way, they would all be neutered and these deformed breeds would be allowed to become extinct. We cannot legislate this, but if we can effect a change of attitude so that pet owners start avoiding brachycephalic breeds, the market for these animals will dry up and breeders will have to move on to more desirable designs.

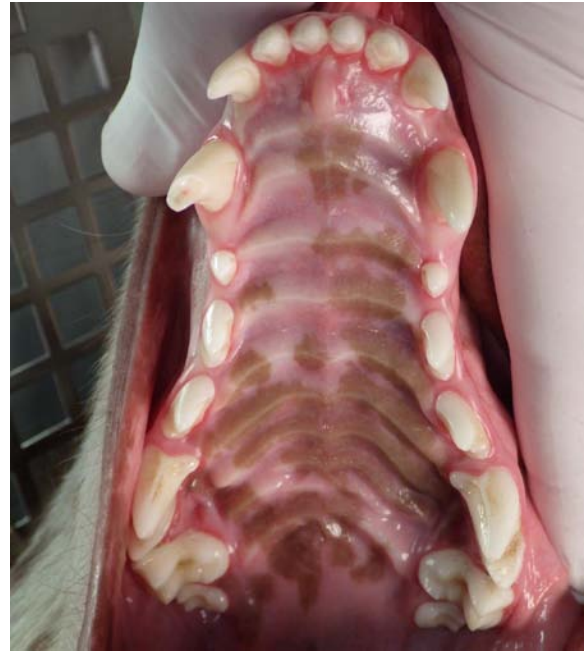I wish I could say it was just the brachycephalic breeds that have these issues. Sadly, such is not the case. [Highly miniaturized breeds](#) are inclined to have teeth that are proportionally far too large for their mouths, leading to many of the same crowding, under-eruption, non-eruption and occlusal concerns seen in brachycephalic dogs of all sizes. But one battle at a time.

In the next issue I will provide some details on and examples of the oral deformities found in brachycephalic dogs. In the mean time, you can get a sense of some of the problems in these previous articles:

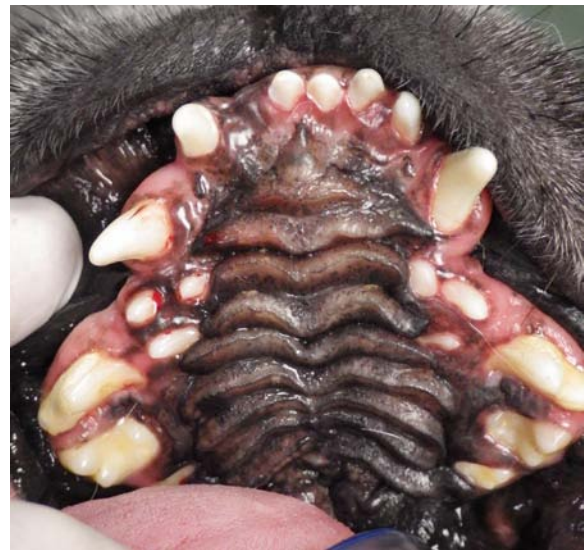www.toothvet.ca/PDFfiles/microdogs.pdf

www.toothvet.ca/PDFfiles/FocusOnBoxers.pdf

www.toothvet.ca/PDFfiles/pericoronitis.pdf



The well-proportioned and constructed maxilla of a border collie (6533)



A horribly deformed, distorted and diseased maxilla of a pug (6500)