

# THE ANATOMY AND PHYSIOLOGY OF THE PERIODONTIUM

## Terminology:

Each tooth has a *crown* and a *root*. The tip of the root is the *apex* and the area around the apex is the *peri-apical* region. Where the root and the crown meet is the *neck* or *cervical region* of the tooth. It is in this area that the enamel covering of the crown ends at the *cemento-enamel junction*. The crown of the tooth is that portion covered by enamel. As you travel from the neck to the tip or *cusps* of the crown, you are traveling *coronally*.

In multi-rooted teeth there is a place where the roots come together to join the rest of the tooth. This crotch-like area is called the *furcation*.

Each tooth has its own name, and there are several systems that have been used. Space allows only a discussion of the Modified Triadan System, which I feel is the best anyway. It refers to each tooth by a three-digit number. The first numeral indicates the quadrant and the next two tell which tooth in the quadrant as counted from the midline to distal.

The number sequence of the quadrants is; permanent upper right = 1, permanent upper left = 2, permanent lower left = 3, permanent lower right = 4, primary upper right = 5, primary upper left = 6, primary lower left = 7, and primary lower right = 8. In each quadrant the first incisor is always 01, the second is 02 and so on. So the right upper fourth permanent premolar is 108, the left mandibular third primary premolar is 607 and the right lower permanent third molar is 411.

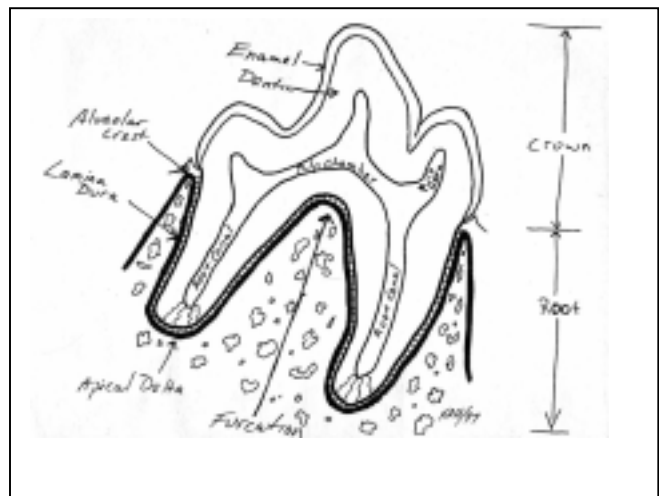
When it comes to the cat, things are not as straight forward. The cat is missing the upper first and the lower first and second premolar teeth and so has second, third and fourth upper and third and fourth lower premolars only. Each quadrant has only one molar. When counting the teeth in the right upper quadrant, with tooth 105 absent, the sequence would go 101, 102, 103, 104, 106, 107, 108, 109. For the lower left quadrant, with the first and second premolar missing, the sequence goes 301, 302, 303, 304, 307, 308, 309.

The Modified Triadan System works for all quadrupeds, as long as the principles are followed. Another feature of the system is the Rule of 4 and 9, which states that the canine tooth is 04 and the first molar is 09 in every quadruped. Any tooth less than 04 must be an incisor and teeth between 04 and 09 must be premolars.

## The Tooth:

Each tooth has a crown and a root. The bulk of a mature tooth is composed of dentin. The dentin of the crown is covered by enamel and the dentin of the root is covered by cementum. The cemento-enamel junction marks the transition from root to crown. Inside the dentin of the root and crown is a hollow chamber filled with the soft tissue known as pulp. This chamber is referred to as the pulp chamber in the crown and the root canal within the root of the tooth.

Enamel is the hardest tissue in the mammalian body. It is composed of crystals of hydroxyapatite arranged in prisms roughly perpendicular to the junction with the underlying dentin. The closely packed crystals



occupy 88% of the volume of the enamel, the remaining 12% being water and organic material. By weight, enamel is 96% mineral. It is acellular and considered non-living.

Enamel is formed by *ameloblasts* during tooth development. Amelogenesis (enamel production) stops prior to tooth eruption and no more enamel is produced. Once the tooth has erupted into the oral cavity, enamel is lost gradually (or rapidly if the animal has a chewing vice) to chemical and mechanical forces. The enamel of most cat teeth ranges from <0.1 to 0.3 mm. In dogs, the range for most teeth is <0.1 to 0.6 mm whereas in humans, the enamel on occlusal tables is usually 2 to 4 mm thick.

Enamel is *relatively* non-porous, impervious and smooth and therefore relatively easy to clean and slow to stain. It acts as an effective barrier to prevent bacteria in the oral cavity from reaching the pulp tissues. Enamel has no sensory capacity and so it protects the underlying tissues from mechanical and chemical irritation. Enamel, though hard, is brittle, tending to shear along the planes of the prisms. A tooth composed entirely of enamel would fracture easily as it has no elasticity or flexibility.

Dentin, which makes up the bulk of canine, feline and human teeth is about as hard as bone but much softer than enamel. It is pale yellow in colour, compared to the stark white of normal enamel. Dentin is roughly 72% mineral, 18% organic matter (mostly collagen) and 10% water by weight.

Dentin is arranged as a collection of tubules running from the pulp towards the enamel. The tubules are roughly 4µm in diameter near the pulp and narrow to 1µm near the enamel.

Lining the inner aspect of the dentin wall is a layer of cells known as *odontoblasts*. These cells extend cytoplasmic extensions into the lumens of the tubules running all the way out to the enamel, therefore, dentin is considered a living tissue. In some of the tubules, unmyelinated nerve fibers lie alongside the *odontoblastic processes* and so dentin is a sensitive tissue that can detect heat, cold, touch and variations in osmotic pressure. All stimuli detected by these nerve endings are registered as pain.

Dentin is produced by cells known as *odontoblasts* on the inside of the tooth throughout the life of the tooth. *Primary dentin* is that dentin which is formed prior to tooth eruption. Normal *secondary dentin* is formed continuously thereafter, causing a gradual reduction in the size of the pulp chamber and is structurally similar to primary dentin. *Irregular secondary* or *tertiary dentin* is formed in areas exposed to injury. It has a distorted collagen pattern, fewer tubules, no nerve fibers and a darker colour than normal dentin.

The collagen component gives dentin some flexibility and allows teeth to withstand considerable forces without fracturing. The overlying enamel may crack and craze, but the dentin can be distorted and return to its normal shape.

The Endodontic System of the tooth consists of the pulp chamber (in the crown) and one or more root canals (within the roots). The pulp chamber has pulp horns, which correspond to the shape of the overlying tooth cusp. With time, the pulp chamber and canals become smaller as secondary dentin is produced. The endodontic system contains the pulp, which is composed of odontoblasts, fibroblasts, various other cells, blood vessels, lymphatics, nerve fibers and ground substance. In the mature dog or cat tooth, the pulp enters the tooth through many tiny openings in the root apex known collectively as the apical delta. There may also be accessory lateral canals further up the root.

The pulp contains unmyelinated fibers, which control vasoconstriction in the pulp and myelinated fibers, which register pain via the trigeminal nerve.

Cementum covers the outer surface of the root. It is in many ways similar to bone and acts functionally as the periosteum for the root. Though physically part of the tooth, it is considered to be part of the periodontal support apparatus. It is discussed later in the section on the periodontium.

Dental Morphology: The teeth of all mammals are categorized as incisors, canines, premolars and molars, according to morphology and function. Dogs and cats use their teeth in much the same way and have similar morphology.

Incisors are the most rostral teeth, with three in each quadrant. In dogs, these single rooted teeth have one, large central cusp and a much lower cusp at either side. They are flat labio-lingually and have a sharp incisal edge. Incisors increase in size from the first to third tooth. The roots are narrower but longer than the crowns. The maxillary incisors have a ridge on the palatal side just above the free gingival margin known as the cingulum. In domestic cats, the incisors are very small with three small ridges along the incisal edge. In the wild, incisors are used to grasp the hide to pull it from the carcass when eating and for grooming of the fur coat.

Distal to the incisors are the single canine or cuspid teeth. These long, single rooted teeth have a simple, conical crown, which tapers to a sharp point. In dogs, the crown curves distally to prevent prey from escaping. In cats the labial face of the tooth will have one or more longitudinal grooves in the enamel. Canine teeth are used for apprehending, holding and killing prey as well as for defense and display.

Distal to the canines are the premolars. In dogs, the first premolar has one simple root and a short, pyramidal crown. The second and third maxillary and second to fourth mandibular premolars all have two roots and a triangular crown with a prominent central cusp and smaller mesial and distal cusps. The premolars are helpful in holding small prey in the mouth and for shearing large chunks of meat from larger prey. These premolars are never supposed to come into contact with the teeth from the opposing jaw.

In cats, the first maxillary premolar is missing and the second may have one root or two fused roots with a single, simple crown. Cats are also missing the mandibular first and second premolars. The maxillary third premolar and the mandibular third and fourth premolars are very similar to those of dogs.

The maxillary fourth premolar of dogs and cats is a three-rooted tooth with a complex crown. There is a long, narrow mesiobuccal root, a shorter mesiopalatal root and a long, wide distal root. The crown has a large mesial cusp and a lower, broader distal cusp with a deep *developmental groove* between them. There is also a cusp above the palatal root. The maxillary fourth premolar is the upper carnassial tooth (meat cutter) which, along with the mandibular first molar (the lower carnassial) acts as a pair of scissors to cut meat from prey.

Molars are teeth, which have flattened occlusal tables and contact each other in order to grind food. The maxillary molars of the dog have three roots each. There is a narrow mesiobuccal root, a narrow distobuccal root and a shorter triangular palatal root. Over the two buccal roots are short, triangular cusps. Over the palatal cusp is the occlusal table, which acts a grinding surface with the lower molars. In the centre of the crown of the maxillary first molar there may be a pit in the occlusal surface, which is prone to the development of caries (tooth decay).

The first mandibular molar in dogs acts as both a premolar and a molar. There are two large roots with the mesial larger than the distal. The large mesial cusp acts as one blade of the scissors in conjunction with the maxillary fourth premolar. The distal cusp is lower and has a ridged occlusal surface, which contacts the mesial portion of the occlusal table of the maxillary first molar. The second mandibular molar has two roots and a ridged occlusal surface, which contacts the distal portion of the first maxillary molar and the mesial portion of the second maxillary molar. The

third mandibular molar has one simple root and a short crown, which contacts the distal portion of the occlusal table of the maxillary second molar.

Cats are true carnivores and have little need to grind their food. The maxillary molar may have one root or two fused roots, which are short and stocky. The crown is oblong and has a low, ridged profile but may never contact the lower molar. The mandibular molar is the lower carnassial as in dogs, but both mesial and distal cusps act as meat cutters. The two cusps are relatively equal in size with a deep developmental groove between them. There are two roots, of which, the mesial is by far the larger. The distal root is quite narrow and supports the distal half of the distal cusp.

### Morphology And Physiology Of The Periodontium

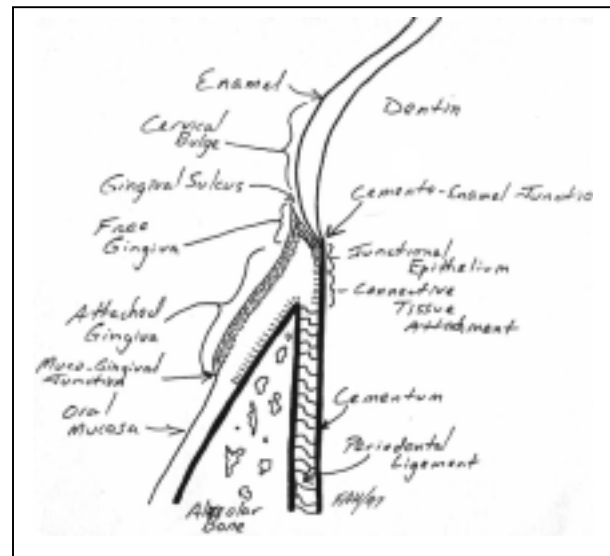
The periodontium consists of the tissues investing and supporting the teeth, including the cementum, periodontal ligament, alveolar bone and gingiva.

The Gingiva is that portion of the oral mucosa covering the alveolar processes of the jawbones and surrounding the necks of the teeth. It is the first line of defense against mechanical insult from mastication and from bacterial invasion of the deeper structures of the periodontium. Anatomically, it is divided into three regions; *marginal* or *free gingiva*, *attached gingiva* and *interdental gingiva*.

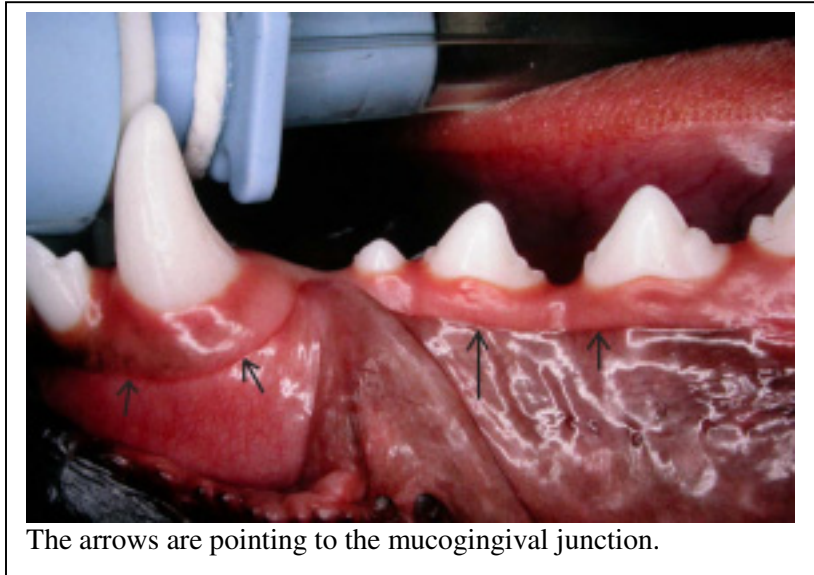
*Marginal gingiva* is the most coronal portion of the gingiva and in normal, healthy patients, it is that portion which is not attached to the tooth, but rather lies passively against it. As it is not attached, there is a potential space between the tooth and the marginal gingiva known as the *gingival sulcus*. The marginal gingiva, therefore, forms the outer wall of the gingival sulcus. The coronal edge of the marginal gingiva is termed the *free gingival margin*.

In germ free animals, the depth of the gingival sulcus is 0 millimeter or very near to it. In all others, even with clinically healthy gingiva, there is a sulcus, the depth of which can be measured by use of a periodontal probe. The normal sulcar depth varies between individuals of the same species, between different species and even between different regions in the mouth of an individual. In the cat, normal depths are between 0.5 millimeter and 1.0 millimeter, with the deeper sulci found in areas where there is the most gingiva such as around the canine teeth. In dogs, normal sulci are from 1.0 to 3.0 millimeters. In humans, normal depths are reported as 2.0 to 3.0 millimeters.

The *attached gingiva* is that portion apical to the marginal gingiva and which is tightly bound to the cementum of the root coronal to the alveolar crest and to the periosteum of the alveolar bone. The facial aspect of the attached gingiva ends apically at a border with the relatively loose and movable oral mucosa. This is seen on the outer surface as the *mucogingival junction*. The mucogingival junction remains stationary throughout life and so as the free gingival margin recedes in periodontal disease, the width of the gingival band decreases. The width of the gingiva differs in different regions of the mouth. In dogs and cats, it is widest over the canines and narrowest around the last molar. On the lingual aspect of the mandible, the attached gingiva ends



at the junction with the lingual alveolar mucosa. The palatal surface of the maxillary attached gingiva blends with the equally firm and immobile palatal mucosa.



The arrows are pointing to the mucogingival junction.

The *interdental gingiva* occupies the space between the teeth. The architecture of the interdental gingiva is dependent on how close the teeth are to each other. In different regions of the mouth teeth may be in close contact, loose contact or no contact at all. In areas of interproximal contact, the area below the contact is called the *gingival embrasure*. If teeth are in close contact at the free gingival margin, there

will be a triangular *gingival papilla* on the facial and lingual/palatal aspect with a valley-like depression known as the *gingival col* in between. If the teeth are in loose contact, there may be a single pyramidal papilla occupying the interproximal space. If teeth are not in contact, the space between them is known as a *diastema*. The diastema will be occupied by gingiva bound to the interdental bone and having a smooth, round contour without a papilla.

Histologically, the gingiva is divided into a connective tissue core covered by stratified squamous epithelium. The epithelium is of three types; *oral epithelium*, *sulcar epithelium* and *junctional epithelium*.

Oral epithelium runs from the crest of the marginal gingiva to the mucogingival junction. It consists of keratinized or parakeratinized stratified squamous epithelium with prominent rete pegs. The keratinocytes are connected to one another by desmosomes and tight junctions. There is evidence that tight junctions allow passage of ions and small molecules from cell to cell. The epithelium is connected to the underlying connective tissue by a *basal lamina*, which is produced by the cells of the *stratum basale*. The basal lamina is permeable to fluids but acts as a barrier to particulate matter.

*Sulcar epithelium* is the thin, non-keratinized stratified squamous epithelial lining of the gingival sulcus. This epithelium has the potential to keratinize if it is exposed to the oral cavity or the bacterial flora in the sulcus is totally eliminated. This suggests that local bacterial irritation prevents keratinization. As a semi permeable membrane, sulcar epithelium is a very important part of the gingival defense mechanism.

*Sulcar fluid*, produced in the gingival connective tissue, passes through the sulcar epithelium as part of the defense mechanism of the gingiva. Studies have shown that following intramuscular injection or oral administration of a number of substances, these same substances can be recovered from sulcar fluid. The list includes substances with a molecular weight of up to one million. It has been suggested that the molecules and ions travel through intercellular spaces without the need to cross cell membranes.

Sulcar fluid is considered an inflammatory exudate in that very little or no sulcar fluid can be collected from strictly normal gingiva and the small amount collected is considered artifact due to

inflammation induced by the collection process. The amount of sulcar fluid produced increases as the degree of inflammation increases. Sulcar fluid is believed to have a cleansing action as it flushes the sulcus of bacteria and particulate matter. Some of the plasma proteins are credited with enhancing adhesion between the epithelium and tooth, thereby slowing the apical migration or impaction of bacteria and foreign matter between tooth and periodontium. The presence of viable leukocytes, immunoglobulins and complement factors all add to the protective properties of the sulcar fluid.

*Junctional epithelium* is a band of non-keratinized stratified squamous epithelium, which forms the *epithelial attachment* to the tooth. The junctional epithelium attaches to the root cementum immediately apical to the cemento-enamel junction. The attachment of the junctional epithelium to the tooth is supported by the gingival fibers, which brace the marginal gingiva against the tooth. Therefore, the junctional epithelium and the gingival fibers are considered a functional unit known as the *dentogingival unit*.

Below the gingival epithelium is the gingival connective tissue known as the *lamina propria*, composed of a *papillary layer* below the epithelium and a *reticular layer* next to the alveolar periosteum. The lamina propria is densely collagenous with a system of collagen fiber bundles called the *gingival fibers*. These fibers brace the marginal gingiva against the tooth, provide the rigidity necessary to withstand the mechanical insults of mastication and unite the free marginal gingiva with the cementum of the root.

The main cellular component of the gingival connective tissue is the fibroblast. It is responsible for the synthesis and secretion of collagen as well as other proteins. Therefore, fibroblasts are responsible for healing of gingiva following surgery or disease processes. Other cells in the gingiva include mast cells and small foci of inflammatory cells. Though the presence of inflammatory cells is almost universal, they are not considered a normal component of perfectly healthy gingiva, but are present as a result of antigenic stimulation. As well as collagen, the gingiva contains other, non-collagenous proteins such as glycoproteins, which mediate attachment of cells to their substrate.

Cementum is a bone-like tissue covering the root of the tooth. It is composed of collagen fibrils and a calcified interfibrillar matrix. Cementum has an inorganic content (45 to 50 %) of hydroxyapatite, which is lower than that of bone (65 %), dentin (70%) and enamel (90%). Primary or acellular cementum covers the cervical two thirds of the root and is formed before the tooth comes into occlusal contact. Secondary or cellular cementum forms around the apical third of the root after the tooth comes into occlusion. It is less regular in architecture and contains individual cells in lacunae that communicate with each other through canaliculi. Both forms of cementum are arranged in lamellae separated by incremental lines parallel to the long axis of the tooth. These more mineralized lines represent periods of rest in cemental formation.

The organic component of cementum is mainly collagen in the form of two types of fibers. One type is the collagen fibers of the cemental matrix produced by cementoblasts, which also produce the interfibrillar ground substance. The other type is the Sharpey's fibers, which are the terminal portions of the principle fibers of the periodontal ligament. Sharpey's fibers are produced by fibroblasts.

Sharpey's fibers make up the bulk of acellular cementum. Most fibers enter at right angles to the long axis of the root and penetrate deep into the cementum but others insert at a variety of angles. The size, number and distribution of Sharpey's fibers increase with function (the more stress on the periodontal ligament, the more Sharpey's fibers). In cellular cementum, Sharpey's fibers make up less of the tissue.

In humans, cemental thickness varies from 16 to 60 microns cervically to 150 to 200 microns apically and in furcations. Cementum deposition continues throughout life so the thickness increases with age. Cementum formation is usually much slower than the formation of bone or dentin.

Cementum is constantly undergoing resorption and repair. As long as the two are in balance, there is no problem. Excessive resorption can be seen as a result of excessive occlusal or orthodontic forces or due to pressure from misaligned erupting teeth, cysts and tumors, embedded teeth, replanted teeth, periapical or periodontal disease. Resorption can also be linked to systemic diseases such as deficiencies of calcium, vitamin D and A and hypothyroidism.

Following a period of resorption, cementum may undergo repair. Repair is often by cellular cementum, separated from the underlying cementum by a darkly staining reversal line. The new cementum re-establishes a functional relationship with the Sharpey's fibers. Cemental repair requires vital connective tissue, so if epithelium proliferates into an area of resorption, repair will not occur.

Ankylosis is fusion of cementum and alveolar bone and obliteration of the periodontal ligament. It can occur as a result of excessive occlusal trauma, chronic periapical irritation and after tooth reimplantation. Ankylosis results in root resorption and healing of the defect with bone. Therefore, ankylosed or reimplanted teeth will often lose their root and exfoliate after 4 to 5 years.

Periodontal Ligament performs a number of vital functions.

- shock absorption of the impact of occlusal forces
- transmission of occlusal forces to alveolar bone
- attachment of the teeth to the alveolus
- maintenance of gingival adaptation to the tooth
- provides a soft tissue casing to protect vessels and nerve in the periodontal space
- supplies nutrients to alveolar bone and cementum via arterioles and drainage via venules and lymphatics
- provides tactile and proprioceptive information which is essential in coordinating the neuromuscular activity of mastication.

The periodontal ligament is the connective tissue that fills the space between the tooth and alveolar bone and attaches one to the other. It is composed mainly of collagen fibers with some elastic fibers, blood vessels, nerves and lymphatics. The periodontal ligament is a relatively cellular region containing fibroblasts, endothelium, cementoblasts, osteoblasts, osteoclasts, macrophages, and the epithelial rest of Malassez.

The main component of the periodontal ligament is the principle fibers. These are bundles of collagen fibers, which follow a wavy course from root cementum to alveolar cribriform plate. The ends of the principle fibers, which are embedded in cementum and alveolar bone, are termed Sharpey's fibers. As well as the principle fibers, there are well-formed bundles of collagen fibers running at various angles and interdigitating with the principle fibers. There are less organized collagen fibers in the interstitium between the principle fibers. These areas contain the blood vessels, lymphatics and nerves of the ligament space.

Fibroblasts are the most numerous cells in the ligament space and are responsible for the production of the collagen. As well as producing new collagen, they have been shown to be able

to phagocytose old collagen fibers and degrade them by hydrolysis, thereby recycling and remodeling the ligament.

The epithelial rests of Malassez are believed to be remnants of Hertwig's epithelial root sheath left after root development is complete. They are found in clusters near the cementum of most teeth and in greatest numbers near the apical and cervical thirds. With age, their numbers diminish through degeneration by becoming calcified to form cementicles. When stimulated, the rest cells may proliferate leading to periapical and lateral root cysts. It has also been suggested that the epithelial rests might be the tissue of origin for canine epulide tumors.

The periodontal ligament is well supplied with sensory nerve endings from branches of the trigeminal nerve. Nerve bundles enter the ligament space from the apical region or through openings in the alveolar bone in much the same way as the blood vessels. These nerves register tactile, pressure and pain sensation. Some nerve fibers end as free, demyelinated nerve endings or as spindle shaped proprioceptors.

Alveolar Bone: The *alveolar process* is the bone, which surrounds and supports the teeth. It forms during tooth eruption and gradually disappears after the tooth is lost. It does not form at all in children with total anodontia. It consists of a thin wall of compact bone against the periodontal ligament (*cribriform plate, alveolar bone proper*) and the cancellous *supporting alveolar bone*. On the lingual and facial aspects, a thin layer of supporting alveolar bone is covered by a plate of compact bone. On radiograph, the cribriform plate appears as a radiodense line known as the *lamina dura*.

Sharpey's fibers embed deeply into the alveolar bone lining the alveolus. The socket wall consists of dense lamellated bone and *bundle bone*. Bundle bone is the term for the bone adjacent to the periodontal ligament because of its content of Sharpey's fibers. Bundle bone is gradually resorbed on the marrow space side and replaced by lamellated bone.

The cancellous supporting alveolar bone consists of trabeculae enclosing irregular marrow spaces lined with a layer of thin endosteal cells. The marrow is generally of the yellow, fatty type in mature individuals, though occasional foci of red marrow may be found near the posterior teeth. The trabecular pattern is quite variable and is affected by occlusal forces.

Like all bone, alveolar bone is constantly remodeling, being resorbed in areas where it is not needed and laid down where it is. When occlusal, orthodontic or other forces are applied to a tooth, it moves within the alveolus and the forces are transmitted to the bone via the periodontal ligament. In areas of tension, osteoblasts produce new bone, whereas in areas of compression, osteoclasts resorb bone. The trabeculae of the cancellous bone are aligned in the path of tension and compression to provide maximum mechanical support for the tooth with the least amount of bone. Forces that exceed these adaptive functions cause trauma to the periodontium and teeth.

When occlusal forces are increased, the number and thickness of trabeculae also increase. If occlusal forces are decreased, the bone undergoes disuse atrophy as bone is resorbed. The number and thickness of trabeculae decreases and bone height is lost. These changes are also influenced by local disease processes, vascular anatomy, systemic disease and the aging process.

#### Changes in the Periodontium with Age

With the passage of time several physiological changes occur in the periodontium, which are aside from the cumulative changes of periodontal and other oral disease processes.

In the periodontal ligament, there is an increase in the number of elastic fibers and a decrease in the vascularity, mitotic activity, fibroplasia, collagen fibers and mucopolysaccharides. The ligament space has been reported to get both wider and narrower with age in humans. The decrease in width is attributed to continued deposition of cementum and bone on either side of the



ligament. In humans, there is a three-fold increase in the thickness of cementum between 11 years of age and 76 years. As the bone and cementum grow toward each other, the ligament may be obliterated. Ankylosis results as cementum and bone fuse. The widening of the ligament space may be due to fewer teeth being available to support the functional masticatory load.

The alveolar bone also undergoes aging changes, many of which are evident radiographically. In a healthy individual these radiographic changes include increased density and coarseness of the trabecular pattern of the cancellous bone, reduced definition of the lamina dura and slight regression of the alveolar crest. Physiologically, there is a decrease in vascularity, metabolic activity and healing ability of the alveolar bone. As resorptive activity increases and bone formation decreases, the porosity of the bone may be increased. Animals suffering from hyperparathyroidism (primary, secondary or pseudo) malnutrition, other systemic disease or local periodontal disease may experience osteoporosis and bone loss. This would not be considered a normal aging change, but is a result of some specific disease process.

### Summary

Although this article has discussed the various components of the periodontium as separate entities, it should be apparent to the reader that there is intimate interconnection and interaction between all of them. The periodontal ligament can only exist where there is cementum on one side and alveolar bone on the other. Some gingival fibers are also considered to be periodontal principle fibers. Blood vessels running through the cancellous alveolar bone penetrate the alveolar bone proper and then go on into the periodontal ligament and gingiva. An integrated understanding of the structure and physiology of all of the components of the periodontium is essential to understanding the pathogenesis and treatment of periodontal disease.

---

---