

MYTHOLOGICAL CREATURES

Unicorns

Most would agree that unicorns are mythological creatures. Everybody thinks they know what one looks like, but nobody has actually ever seen one. So it is with several things in veterinary dentistry. There are a few concepts that get mentioned often but that actually do not exist at all or are exceedingly rare.



I have a paper that dispels a variety of myths:

www.toothvet.ca/PDFfiles/mythology.pdf

and another that exposes a variety of truths:

www.toothvet.ca/PDFfiles/Dental_Truths.pdf.

Now let's look at some mythological creatures in veterinary dentistry.

The Routine Dental Prophylaxis

General practitioners often talk of animals having a "routine dental prophylaxis". This is something that simply does not exist.

"Routine" is not a word that can be used when describing a dental procedure. Dogs are supposed to have 42 teeth and cats are supposed to have 30. Each tooth may be present or absent. If present, each tooth may have a number of different pathological processes affecting it. Then there are the lips, tongue, palate and buccal mucosa, all of which may be affected by a variety of conditions. There are brachycephalic, mesiocephalic and dolicocephalic head shapes. Therefore, the number of combinations and permutations extend into the thousands. If you know what to look for and you look carefully, almost every dental patient will have some

hidden pathology that was not part of the pre-operative problem list. Those few cases that have no surprises are so rare as to constitute a surprise in their own right.

So, every case is different, the majority hold surprises and no one scenario is common enough to be considered routine.

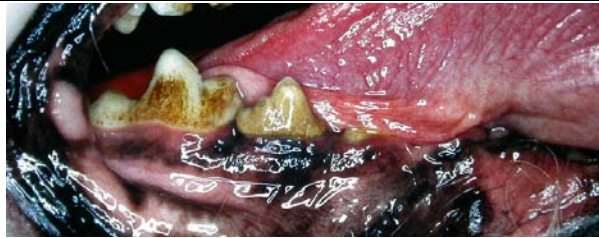"Prophylaxis" is short for prophylaxis, which is a fancy word for prevention. The vast majority of pets presented for dental treatment already have detectable dental disease (gingivitis is disease) and so it is far too late to be thinking of prevention. Prevention is what you do before there is disease so that disease does not have a chance to develop (vaccines are prophylactic). A bit more about this issue can be found here - www.toothvet.ca/PDFfiles/PerioAgain.pdf.

Why bother making this point? Well, if you estimate/schedule and prepare your client and staff for a "routine prophylaxis", you have set yourself up for all manner of disappointment. Here are some possibilities:

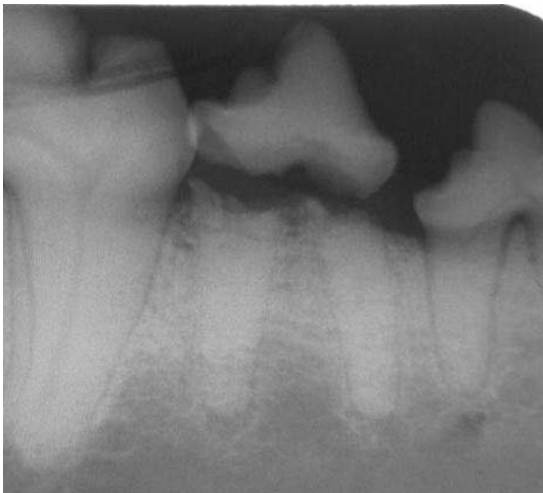- If you schedule for a "routine prophylaxis", you have closed your mind to the possibility of surprises and so you are less likely to look thoroughly to find them. If you don't look with open eyes and open minds, you will miss pathology, leave it untreated and send your patient home to continue to suffer in silence.
- If you schedule for a "routine prophylaxis", when you do find surprises, it throws your schedule for the day way off which adds to the stress of the day for you and all of your staff.
- If you estimate for a "routine prophylaxis" when you find surprises, you now have to get in touch with the owners to obtain informed consent for the new plan and new estimate. Many owners find this sort of "bait and switch" very upsetting.

So do everyone a favour and delete "routine prophylaxis" from the vocabulary of the practice. Get a big pickle jar and anytime someone is caught uttering these vile words, have them drop a loonie (Canadian \$1 coin bearing the likeness of a loon on the tails side) in the jar. Use the collected money to buy some new dental hand instruments.

Instead, expect that every dental patient will have more going on than you can possibly see in the front office. Make it very clear to the owners that your initial treatment plan and estimates are very tentative and that you WILL be contacting them intra-operatively to discuss the new findings, to adjust the treatment plan and the estimate based on the new findings.



The photograph of the clinical situation suggests a cleaning is needed, but no obvious signs of anything more involved than that.



The radiograph shows one of the very many surprises you might find once your patient is anesthetized.

And when scheduling your dental procedures be sure to leave time in the schedule to account for the time it will take to deal with the surprises. Nine times out of ten you will need this extra time.

There is nothing wrong with hoping for the best, but you would be wise to prepare for something much worse.

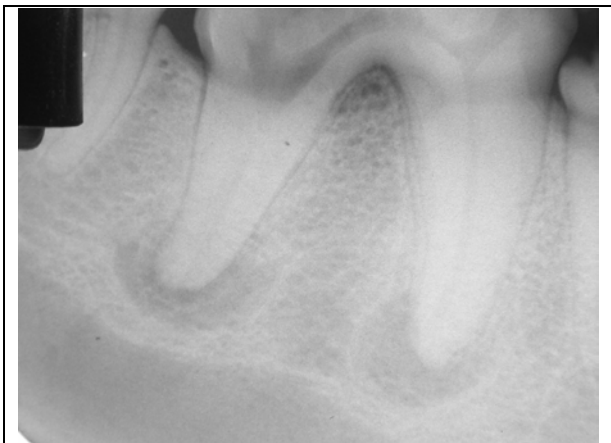Tooth Root Abscess

While a common diagnosis, these are as rare as hen's teeth. I have been doing nothing but dentistry for 22 years and have seen thousands of horribly infected teeth/mouths. I think I have seen fewer than 5 cases that I would actually refer to as dental abscesses.

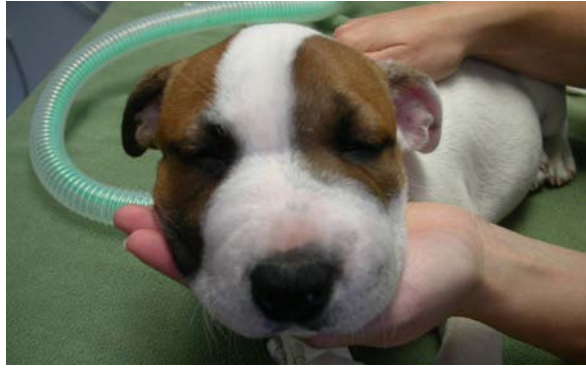An abscess is a closed area of sepsis that has no outlet for drainage.

With periodontal disease, there may be pus oozing from below the gum line, but with the tooth sitting in the middle of the lesion, the tooth acts like a drain, keeping the wound open. So this is not a closed lesion and therefore it is not an abscess.

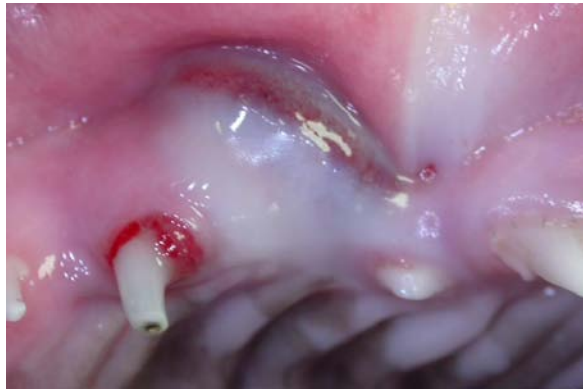
With endodontic disease in the form of septic pulp necrosis there is rarely any pus anywhere. Once the pulp is dead, the endodontic chamber contains dead pulp tissue, bacteria, food, hair... but no living animal tissue and there is no blood supply to provide the white blood cells for the formation of pus. As the bacteria ooze out through the apical delta(s), there will be an apical periodontitis which almost always leads to the development of an apical granuloma, not a pocket of pus.



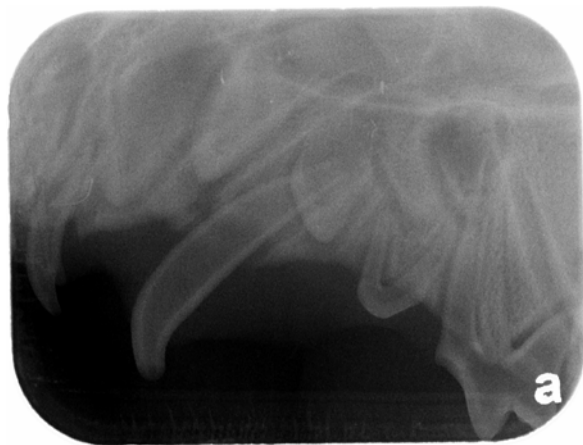This radiograph of a dog's lower right first molar shows significant apical lucencies indicative of chronic apical periodontitis. These are NOT tooth root abscesses. These are lesions of endodontic origin and are almost certainly apical granulomas. We cannot tell for sure from a radiograph.



A puppy with an acute facial cellulitis.



Intra-orally we can see the open pulp chamber in the crown of the left upper primary canine tooth and intra-oral swelling and inflammation.



And the radiograph shows that the large pulp chamber with a wide-open apex and on open crown means that this tooth can act as a drain, letting infection in and drainage out. No Abscess here.

In time, the apical periodontitis may fenestrate through the alveolar bone allowing sepsis into the facial soft tissues. This results in an acute

facial cellulitis (not an organized pocket of pus). This may then fistulate through the skin (or the oral mucosa) leading to a draining tract. Since this is draining, even if the discharge is purulent, it is still not an abscess.

Again, you could ask why I am splitting this hair. Well, the standard treatment plan for an abscess is to establish drainage and treat with an appropriate antibiotic. Such an approach will be of virtually no benefit for a dental infection.

My papers on antibiotics are here:

www.toothvet.ca/PDFfiles/Antimicrobials.pdf

www.toothvet.ca/PDFfiles/Antibiotics.pdf

If the source of the infection is endodontic disease, then the tooth needs [root canal treatment](#) or extraction - end of story. If the source of the infection is periodontal disease, then the tooth needs periodontal surgery or extraction - period. As long as the source or portal-of-entry for the infection remains in place, no amount of drainage or antibiotics are going to fix the problem.

Another concern I have with the diagnosis of "tooth root abscess" is that it is often used as justification for failing to close oral surgical sites. The wounds may be "left open to drain". However, open oral wounds do not drain. They get plugged and contaminated with food and hair and all manner of debris. And these wounds involve exposed bone.

So, put aside the idea of a "tooth root abscess" and the idea that dental infections can be treated with antibiotics and drainage. Such an approach simply will not work.

Extraction sites must be adequately debrided to remove diseased tissue and then the wound closed to keep it from becoming re-contaminated.