

## “Missing” Teeth?

The anatomy textbooks tell us that dogs should have 42 permanent teeth and cats should have 30. Unfortunately, some dogs and cats forget to read the book. As a result, some have extra (supernumerary) teeth while others are missing some.

If a tooth is actually missing, it is often of no consequence. In fact, for many dogs, having fewer than the normal compliment of teeth is a distinct advantage. Take for example the Shih Tzu, with its very short maxilla. If all 20 maxillary teeth are present, there is insufficient room for them to line up properly, so there is dramatic rotation and crowding. The result typically is early onset of periodontal disease and loss of many teeth. So in small dogs, having a few missing teeth allows more room for those that do develop.

When I see an animal for the first time, if I detect a “missing” tooth, I do not know for sure if the tooth is completely missing, partially missing or hiding and this is very important information to have. In order to document the situation, I always like to take an intra-oral dental radiograph of the area.

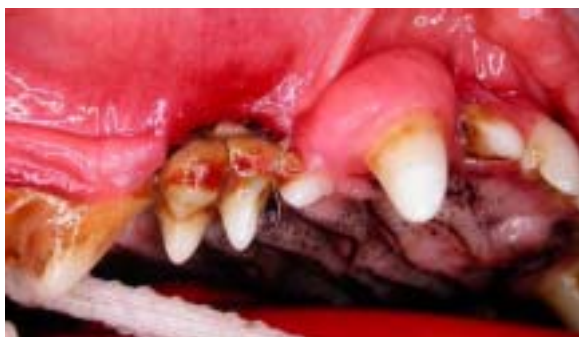If the tooth is missing completely:

If the radiograph reveals no evidence of dental tissues where there should be a tooth then I conclude that the tooth was congenitally absent, unless the history indicates that the tooth was extracted previously.

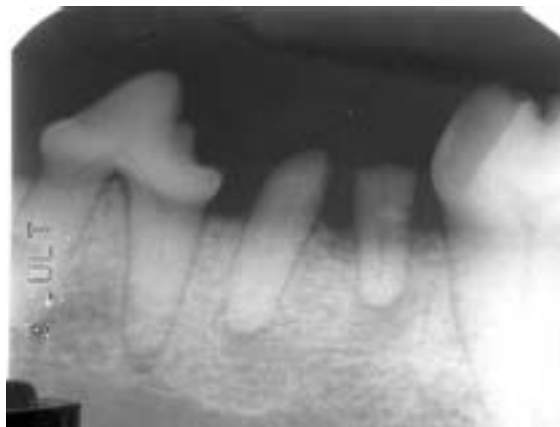If the tooth is missing, no treatment is needed. The missing tooth is duly noted on the dental chart for future reference and we never have to worry about it again.

If there is a retained portion of the tooth:

It is not uncommon to find a portion of root retained where once there was a tooth. This may be the result of a tooth fracture, which left a portion of the root behind as the rest of the tooth fell away or it may be the result of an incomplete extraction.



There was so little room in this mouth for the premolars that the second and third had to turn sideways to fit in. There was also no space for a good collar of gingiva between these teeth, so early onset of periodontal disease was inevitable. Selective extraction of the third premolar in the first year of life would have dramatically improved the prognosis for the remaining teeth. The result of inaction was that instead of losing one tooth, she lost four as well as needlessly enduring years of infection.



This radiograph shows the retained roots of the left mandibular fourth premolar. The tooth suffered a crown/root fracture in which the crown was lost but the roots remained in place. Though it may not reproduce well here, the original radiograph showed obvious evidence of endodontic disease in the form of decreased bone density around the apices of both roots. The distal root (to the right) is being extruded (pushed up) from the alveolus by the slight but constant pressure of the inflammatory response at the apex. Both these roots were protruding through small defects in the gingiva, which had tried to heal over but had failed. As the roots were exposed to the oral cavity, it was inevitable that bacteria would work their way down the pulp chambers and out the root tips to cause periapical infection.

When a retained root remnant is discovered, a decision needs to be made regarding what to do about it. This decision is based on several other bits of information.

Examine the gingiva over the retained root very carefully (with good light, magnification and a periodontal probe). You are looking for even the tiniest of fistulas in the soft tissue leading down to the root remnant and/or inflammation in the overlying gingiva. If there is even a hint of a fistula or inflammation, the root must come out.

Next, examine your dental radiograph (again with magnification – these are small structures). Look for any evidence of decreased bone density in the periapical region or a widening of the apical periodontal ligament space. Also look for evidence of bone loss around the coronal end of the root. If there is any radiographic evidence of disease around the root it must come out.

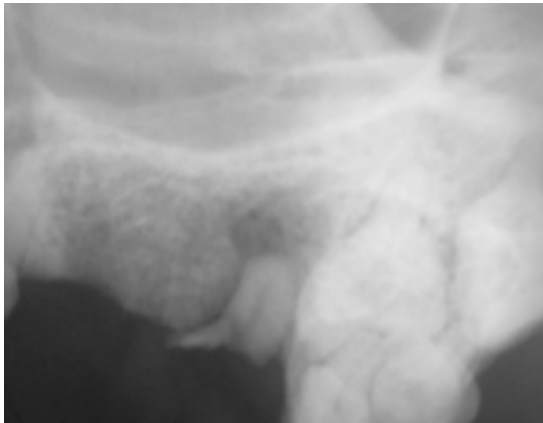
If the clinical and radiographic examinations reveal healthy, intact gingiva over the root and healthy bone surrounding it, you might opt to leave the root in place. If you do leave any root remnants in place, you must disclose this information to the owners and document it in your permanent records.

If the tooth is present but unerupted:

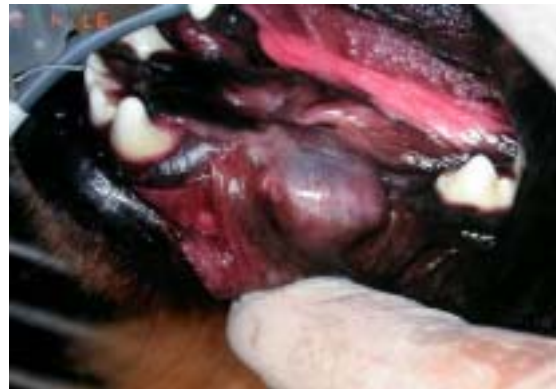This was really the situation that inspired me to write this article in the first place; it has just taken me a while to get around to it. Teeth that have developed but fail to erupt for any reason can be a serious source of trouble and need to be found and removed before the trouble begins.

When a tooth is developing within the jawbones, one of the first things to develop is the *enamel organ*. This structure is composed of the *inner enamel epithelium* and *outer enamel epithelium* with *stellate reticulum* between these two single-celled layers. The cells of the inner enamel epithelium are also known as *ameloblasts* and it is their job to produce the enamel that will cover the crown of the tooth.

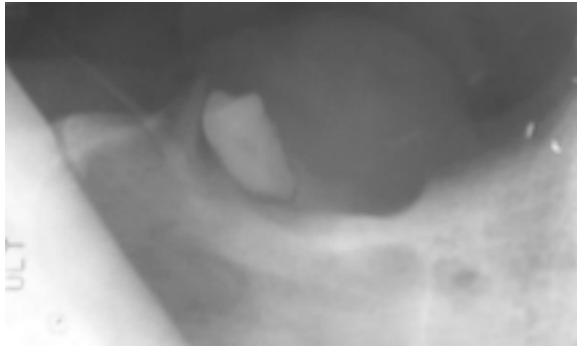
Once the enamel organ has completed this task, the stellate reticulum atrophies and the inner and outer enamel epithelia collapse on each other to produce a thin sac surrounding the crown known as the *reduced enamel epithelium*. The reduced enamel epithelium is attached to the tooth at the



This dog was referred for evaluation of a recurrent infra-orbital swelling. The referring veterinarian had extracted the maxillary fourth premolar but the swelling recurred after cessation of antibiotic treatment. The radiograph shows a large remnant of the distal root of the tooth still in place. This was a result of an incomplete extraction. Though the gingiva had completely healed over this root remnant the obvious periapical osteomyelitis and recurrence of the facial swelling indicate that this root remnant needed to be removed.



This large, non-painful, fluid-filled intra-oral swelling was found in a 1.5-year-old chow chow. Note that some premolars appear to be missing in this area. Aspiration of this swelling would have revealed a straw-coloured, mucoid fluid. The soft tissue overlying the swelling has a distinctive blue cast to it.



This pre-operative radiograph of the cyst area shows that the second premolar (tooth 306) is actually missing but the first premolar (tooth 305) is present yet unerupted. A very large cyst had developed around this seemingly insignificant tooth.



This intra-op radiograph shows the full extent of the cyst, which destroyed the periodontal support over a large area of the canine tooth. As well as removing the unerupted premolar and the cyst lining, the canine tooth was also lost.

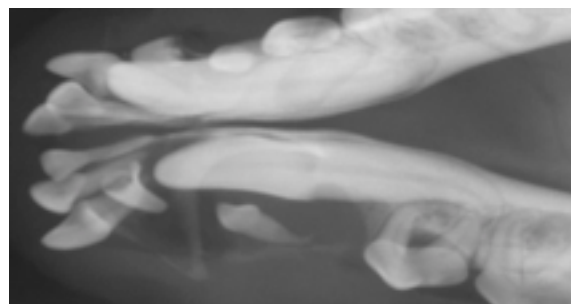
*cementoamel junction* (where the cementum covering the root meets the enamel covering the crown).

When the tooth erupts into the mouth, it breaks through the gingiva and most of the delicate reduced enamel epithelium covering the crown is lost. A small collar of reduced enamel epithelium remains attached to the tooth near the cementoamel junction to form the *junctional epithelium* (part of the gingival attachment to the tooth).

When a tooth fails to break through the gingiva, the reduced enamel epithelium remains as an intact sac of tissue completely encasing the crown of the tooth and attached at the cementoamel junction. In time (sometimes weeks, sometimes months or even years), the inner layer of this sac may start to produce fluid. As the sac fills with fluid (usually straw-coloured and slightly mucoid), it puts pressure on the surrounding bone, which then is resorbed, leaving room for the fluid-filled balloon to grow even larger. This balloon is known as a *dentigerous cyst*.

As long as the cyst remains encased in bone, there are no external signs of the trouble going on below the surface. Once the cyst gets large enough to break through the bone somewhere, a fluid-filled, non-painful intraoral swelling will develop and that is when the problem becomes obvious. Unfortunately, by this time, the cyst has often grown large enough to destroy the bone supporting the roots of one or more adjacent teeth.

Treatment for dentigerous cysts involves removal of the unerupted tooth as well as the entire cystic lining. If the cyst wall is left in place, the problem will recur. As well, any adjacent teeth that have lost a significant portion of their alveolar bone will have to be removed.



This unerupted canine tooth resulted in the development of a dentigerous cyst, which destroyed all the bone supporting the mandibular incisors and much of the bone around the second premolar. You can also see the first premolar floating in the cyst, indicating that it had been impacted as well. Superimposed over the incisor roots, the crown of the deciduous canine tooth is evident, indicating that this tooth had also failed to erupt. So much bone had been lost that there was a real risk of spontaneous mandibular fracture. Treatment involved very careful extraction of the incisors, the canine, the first two premolars and cyst lining.

**Far better than treatment for dentigerous cysts is their prevention!** Once an animal has reached six or seven months of age, all of the permanent teeth should have made an appearance, though they may not all be fully erupted by that time. At this time, it is a simple matter to count all the teeth in the mouth and see if there are any that appear to be missing. Spay/neuter time affords a perfect opportunity to do this in an anesthetized patient, but it is quite possible to do this examination in a conscious patient.

If any teeth appear to be missing, get dental radiographs right away. If the tooth is found to be present but unerupted, have it removed before a large cyst develops. If this had been done for the chow chow depicted on the previous page, it would have been a simple, quick and inexpensive surgery. Since that was not done, a large cyst developed necessitating a much larger surgery, loss of the canine tooth and stressing the client who was concerned that the swelling was a malignancy.

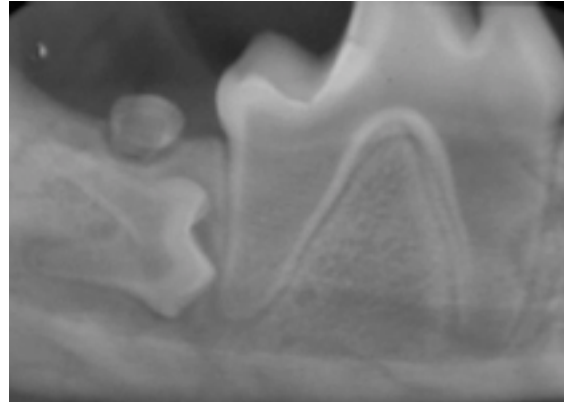
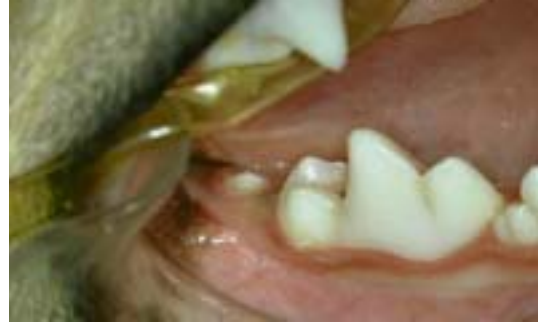In my experience, the tooth most likely to be unerupted is the mandibular first premolar. Usually it fails to erupt because it is lying horizontally (or close to it) within the mandible instead of standing up straight. I have also seen eruption failures affecting upper first premolars, lower third molars, canine teeth, the lower second molar and more.

The Take-Home Message:

***Every tooth is present until proven otherwise by radiographic evaluation.*** If you find a tooth hiding, get it out before a destructive dentigerous cyst has time to develop. If you find a retained remnant of a

tooth, many times it will also be causing trouble and will require removal. A “wait-and-see” approach only gives time for things to go from bad to worse and such a treatment plan cannot be justified. Neither is it appropriate to delay definitive diagnostics and treatment by dispensing antibiotics on speculation.

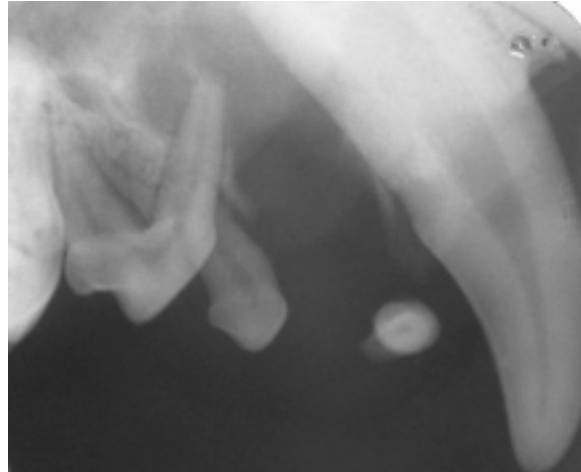
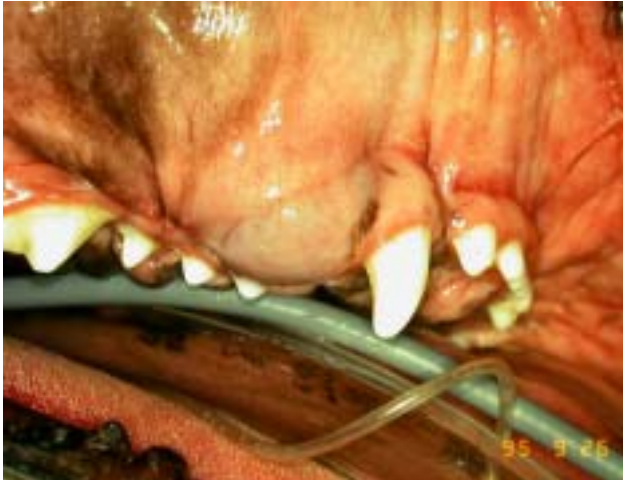If you see a smooth swelling in mouth, especially if it has a blue tinge to it, a dentigerous cyst should be your first rule-out and a radiograph your first action (forget aspiration – an xray will give you your answer far more certainly).



The patient is a six-month-old JRT. In the photo, the first molar is evident and so is something that looks like the third molar, but there is nothing resembling the second molar. The radiograph shows why. The second molar is rotated 90 degrees and is lying horizontally within the mandible. This tooth required immediate removal. Delay would allow the development of a cyst, which would destroy the bone support for the first molar, a tooth we definitely wanted to protect from such harm.

One More Curve:

I have seen a few dentigerous cysts in mouths that seemed to have all their teeth. The problem was an unerupted supernumerary tooth. So if you see what looks like a fluid-filled swelling in a mouth, even if all the teeth appear to have erupted normally, take an intra-oral dental radiograph. In fact, any time you have any lesion in the mouth, an intra-oral dental radiograph is likely going to be indicated.



This one-year-old boxer had blue-tinged swellings distal to both maxillary canine teeth. Aspiration by the referring veterinarian revealed a straw-coloured mucoid fluid and always the swelling returned (had been aspirated several times starting around six-months of age). Though the photo suggests that all teeth are erupted (you can see the canine and four premolars), the radiographs showed that this dog had supernumerary first premolar and one on each side failed to erupt, giving rise to the cysts. Rather than aspirating these lesions, radiograph them then get out the offending tooth and the cyst lining. In this case, I removed the unerupted first premolar, the erupted first premolar and the second premolar. On radiographic follow-up a year later, the defect in the bone had healed completely.