







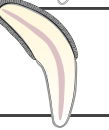













# Radiographic Notes - Canine

## Right maxilla

Findings

Findings

## Left maxilla
















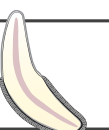





 101			201 
 102			202 
 103			203 
 104			204 
 105			205 
 106			206 
 107			207 
 108			208 
 109			209 
 110			210 

## Right mandible

Findings

Findings

## Left mandible

 411			311 
 410			310 
 409			309 
 408			308 
 407			307 
 406			306 
 405			305 
 404			304 
 403			303 
 402			302 
 401			301 